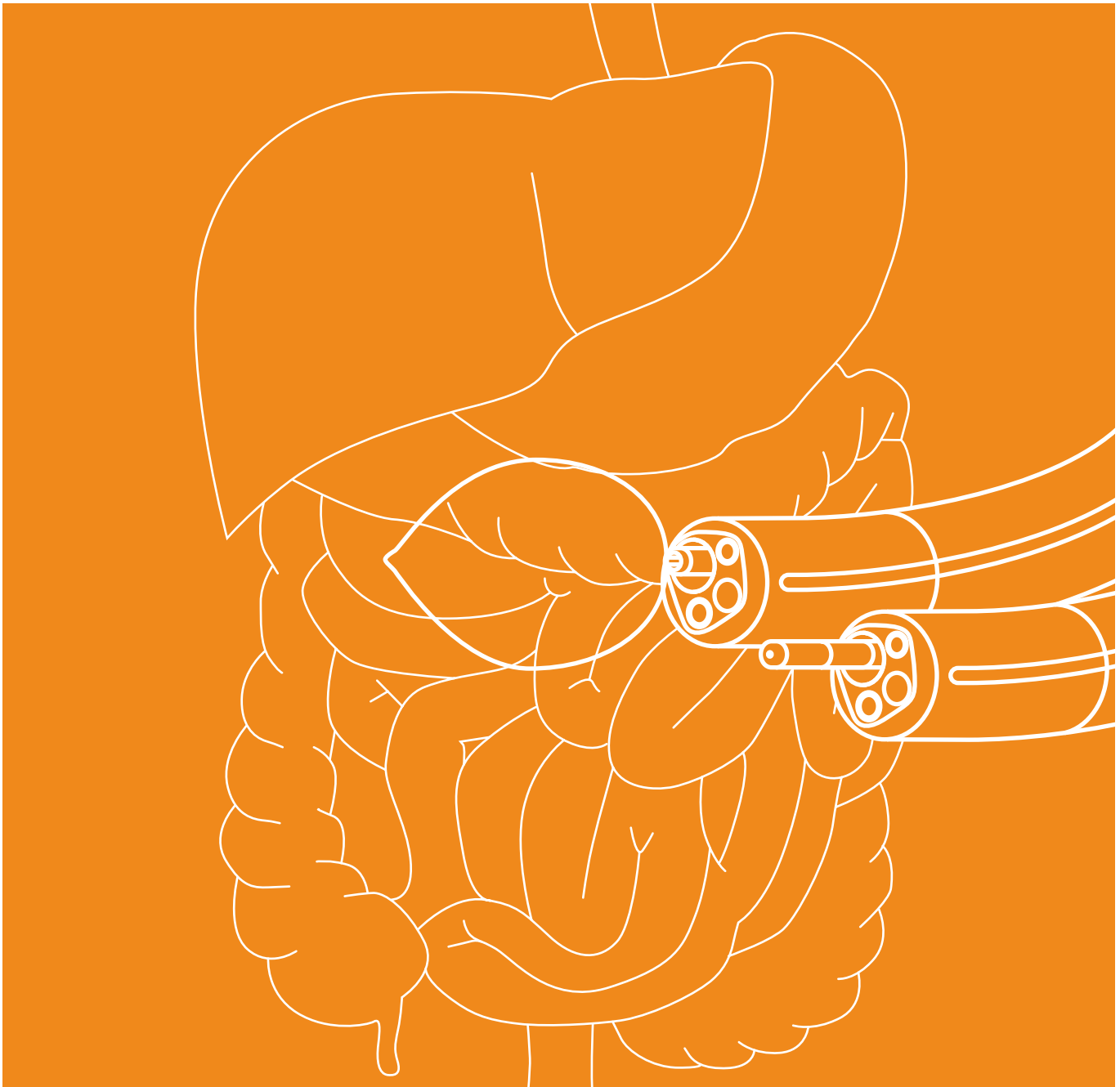


GASTROENTEROLOGY



BOWA ELECTROSURICAL SYSTEMS FOR USE IN GASTROENTEROLOGY
THE FUNDAMENTALS OF HIGH-FREQUENCY ELECTROSURGERY | ARGON PLASMA COAGULATION (APC) | PRACTICE &
METHODS | RECOMMENDED SETTINGS | REFERENCES

IMPORTANT NOTICE

While every effort has been made by BOWA-electronic GmbH & Co KG to ensure that the information provided in this brochure is accurate, occasionally errors may occur.

BOWA accepts no liability for the recommended settings listed, or any of the information or figures provided in relation to these settings. Liability is restricted to instances of wilful misconduct or gross

negligence information pertaining to recommended settings, sites of application, duration of application, and device usage are based on clinical experience. Some centres and physicians may prefer different settings to those recommended in this brochure.

Specifications are for guidance only. Their relevance and applicability should be confirmed by the operating surgeon.

Depending on individual circumstances, it may be necessary to deviate from the specifications provided in this brochure.

With research ongoing, and new clinical evidence emerging, medical knowledge and practice continue to evolve. As a result, a situation may arise in which it is advisable to diverge from the specifications provided.

COPYRIGHT

All of the contents and materials published in this brochure are subject to German copyright law.

Contents or materials may not be copied, edited, distributed or processed without

prior written permission from BOWA-electronic GmbH & Co. KG.

TABLE OF CONTENTS

1		FUNDAMENTALS OF MODERN HIGH-FREQUENCY SURGERY			4
1.1		A Brief History of Electrosurgery			4
1.2		Fundamentals of Modern High-Frequency Surgery			4
1.3		Electrocoagulation			4
1.4		Electrotomy			4
1.5		The Monopolar Method			5
1.6		Argon plasma Coagulation			5
1.7		The Bipolar Method			5
1.8		Tissue Sealing			5
1.9		Electrosurgery – General			6
1.9.1		Safety Precautions to Prevent Electrosurgical Complications			6
1.9.2		Neutral electrode			6
1.10		Integrity of Equipment			7
1.11		Neuromuscular Stimulation (NMS)			7
1.12		Contact with Conductive Objects			7
2		PRACTICE & METHODS			8
2.1		Gastrointestinal bleeding	9	2.3.4	Piecemeal polypectomy 16
2.1.1		Ulcer bleeding forrest class IB-IIB	9	2.3.5	Endoscopic full-thickness resection 16
2.1.2		Oesophageal varices	9	2.4	Incision 16
2.1.3		Vascular malformation and vascular ectasia	10	2.4.1	Papillotomy 16
2.1.4		Haemostasis/coagulation – APC	11	2.4.2	Zenker’s diverticulum 17
2.2		Neoplasms	11	2.4.3	Achalasia 17
2.2.1		Barrett’s oesophagus	11	2.5	Tumour debulking and ablation 18
2.2.2		Oesophageal cancer and Barrett’s cancer	11	2.5.1	Tissue necrosis – APC 18
2.2.3		Benign oesophageal tumours	12	2.5.2	Treating tumours – APC 18
2.2.4		Gastric adenocarcinomas	12	2.5.3	Recanalisation of strictures/stenoses 18
2.3		Resection	13	2.6	Additional procedures 18
2.3.1		Polypectomy	13	2.6.1	Oesophagus – miscellaneous 18
2.3.2		Endoscopic mucosal resection (EMR)	15	2.6.2	Stomach – miscellaneous 18
2.3.3		Endoscopic submucosal dissection (ESD)	15		
3		OVERVIEW OF RECOMMENDED SETTINGS			20
4		DIAGNOSES AND RECOMMENDED PROCEDURES			23
5		FAQ – BOWA ARC IN GASTROENTEROLOGY PRACTICE			25
6		REFERENCES			27

1

FUNDAMENTALS OF MODERN HIGH-FREQUENCY SURGERY

1.1 | A BRIEF HISTORY OF ELECTROSURGERY⁽¹⁾

The concept of using heat to treat tissue is first documented in ancient Egyptian papyrus scrolls, continued down through Greek and Roman times in the form of the ferrum candens (cauterizing iron) and is further evidenced in the use of the ligatura candens (cutting snare) following the invention of galvanocautery in the 19th century.

However, the development of high-frequency surgery (HF surgery) as we know it today did not begin until the 20th century. HF surgery involves the generation of heat inside the tissue itself, whereas previous techniques required the transfer of thermal energy from the heated instruments employed.

The first multi-purpose devices based on thermionic valves were developed in 1955, followed by transistor-based devices in the 1970s and argon beamers in 1976. Microprocessor-controlled HF surgical devices have been available since the early 1990s. These high-precision instruments first made it possible to modify a range of parameters enabling precise adjustment of the electric current for specific treatment purposes.

1.2 | FUNDAMENTALS OF MODERN HIGH-FREQUENCY SURGERY⁽¹⁾

Depending on its nature, value and frequency, the action of electrical current on tissue may be electrolytic (destructive), faradic (stimulating nerves and muscles) or thermal. HF surgery uses alternating current at frequencies of at least 200 kHz, with the thermal effect predominating. The thermal effect mainly depends on tissue-current exposure time, current density and the specific resistance of the tissue, which basically declines as the water content or blood supply increases. Another important practical factor to consider is the portion of current flowing past the target site, possibly leading to thermal damage in other areas (for example during irrigation, the risk being higher with monopolar than bipolar techniques).

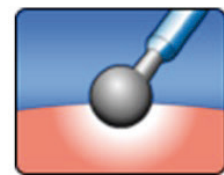
1.3 | ELECTROCOAGULATION⁽¹⁾

A coagulation effect is produced when tissue is heated very slowly to more than 60 °C.



BOWA ARC 400 Electrosurgical Unit

This process of coagulation results in numerous changes to the tissue including protein denaturation, evaporation of intracellular and extracellular water, and tissue shrinkage.



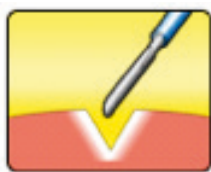
Mode icon for moderate coagulation

Various types of coagulation are used in HF surgery. The techniques differ according to the characteristics of the electric current and route of administration and include contact coagulation, forced coagulation, desiccation (coagulation using an inserted needle electrode), spray coagulation (fulguration), argon plasma coagulation (APC), bipolar coagulation and bipolar tissue sealing.

1.4 | ELECTROTOMY⁽¹⁾

A cutting effect is achieved by raising tissue temperature very rapidly to more than 90–100 °C, producing a build-up of steam in the cells which destroys the cell walls and then acts as an insulator. An arc voltage thus develops between the electrode and the tissue, ultimately causing (recur-

rent) sparking at voltages starting from about 200 V with a very high current density at the base points. This arc will form regardless of the surrounding media (e. g., air or liquid).



Mode icon for standard cut

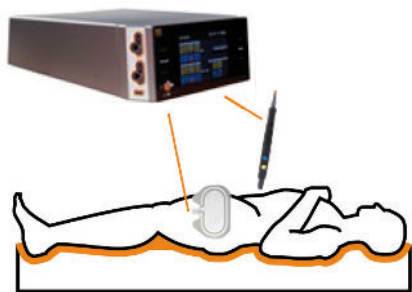
HF surgery enables additional coagulation of wound margins by modulating the current (voltage elevation with pauses). The type of cut may be smooth or jagged depending on the intensity. BOWA arc generators can fine-tune the degree of jaggedness to as many as 10 different levels depending on the requirements.

Other thermal effects of current with less relevance in HF surgery include carbonisation (charring starting from approx. 200 °C) and vaporisation (at several hundred degrees Celsius).

1.5 | THE MONOPOLAR METHOD⁽¹⁾

Monopolar HF surgery uses a closed circuit in which current flows from the instrument's active electrode through the patient to the large-surface neutral electrode and back to the generator.

The area of contact between the tip of the monopolar instrument and the patient's tissue is small. The highest current density in the circuit is achieved at this point, thereby producing the desired thermal effect.



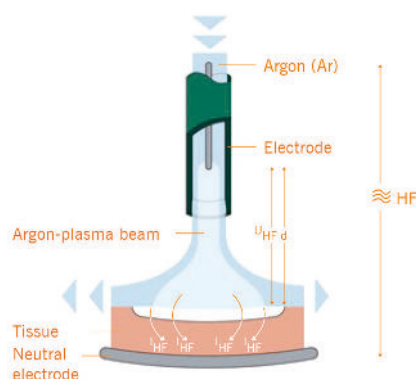
Monopolar operating principle

The large surface area and special design of the neutral electrode acting as the opposite pole hence reduce local build-up of heat to a minimum.

1.6 | ARGON-PLASMA COAGULATION (APC)⁽¹⁾

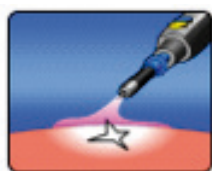
APC is a monopolar method in which the HF current flows through ionised argon gas into the tissue in a manner that avoids direct contact between the electrode and the tissue (non-contact method) and hence prevents adhesion of tissue to the electrode.

Argon is a chemically inert and non-toxic noble gas found naturally in the air. It is delivered through a probe to the surgical site and flows in the ceramic tip past a monopolar HF electrode to which a high voltage is applied. Once the required field strength has been reached, a process of ionisation to plasma begins and a blue flame appears (the "argon beam").



Operating principle for Argon Plasma Coagulation

The electrically conductive plasma is directed automatically in the beam to the point of lowest electrical resistance and coagulates the tissue at that location at temperatures starting from 50–60 °C. The gas keeps oxygen away and so prevents



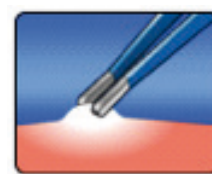
Mode icon for Argon - open

any carbonization (charring) that might otherwise impede the surgeon's view due to smoke production and result in poor wound healing or postoperative bleeding.

These effects enable safe procedures with a low rate of complications, facilitating effective coagulation and devitalisation of tissue anomalies while providing homogeneous surface coagulation at limited penetration depths.

1.7 | THE BIPOLAR METHOD⁽¹⁾

In bipolar HF surgery, the current is restricted locally to the area between the two active electrodes integrated in the instrument and does not flow through the whole of the patient's body. Hence, a neutral electrode is not required.



Mode icon for bipolar method

1.8 | TISSUE SEALING

Conventional electrocoagulation is unsuitable for blood vessels with diameters exceeding approximately 2 mm. Bipolar tissue sealing or ligation is necessary to be sure of achieving haemostasis and a durable vessel seal. The vessel or tissue bundle is grasped using a special instrument and compressed at a constant defined pressure. A number of automatically controlled cycles of electric current with adjustable electrical parameters depending on the tissue type are then applied to fuse the opposing vascular walls together.

Individual visualisation of the vessels prior to the procedure is unnecessary in most cases. Entire tissue bundles containing vessels can be grasped and fused. The desired effect is indicated by a translucent white coagulation zone within which the tissue can be safely separated. In individual cases it may be advisable to seal the vessel in two places some distance apart and make an incision between those sites. Bipolar sealing is technically feasible up to a vessel diameter of approximately

10 mm and has been clinically validated for diameters of up to 7 mm.



Mode icon LIGATION


Since the tip of the instrument will be hot, care should be taken to maintain a safe distance from susceptible tissue structures and to avoid inadvertent coagulation as a result of accidental touching or when setting down the instrument.



Ergo 310D

Various studies⁽²⁻⁶⁾ have demonstrated that vessels sealed in this manner remain sealed. Burst pressure in these studies was higher than 400 mmHg in more than 90% of cases (in some cases as high as 900 mmHg) and thus well above the blood pressures of around 130 mmHg typically encountered in real life.

Histology shows that haemostasis in conventional coagulation involves shrinkage of the vessel wall and thrombus development.



Process of vessel sealing

In contrast, vessel sealing is associated with denaturation of collagen with fusion of the opposing layers, while the internal elastic membrane remains largely intact since its fibres only undergo denaturation at temperatures above 100 °C.

A transition zone exhibiting thermal damage of about 1–2 mm in width and

immunohistochemical changes of about double that width is observed lateral to the sharply circumscribed homogeneous coagulation zone. Sterile resorptive inflammation then develops mainly in the surrounding connective tissue with no evidence of even temporary seal failure.

The advantages of bipolar vessel sealing over other methods such as ligation, sutures and vascular clips include the speed of preparation, rapid and reliable sealing of vessels, the certainty that no foreign materials will be left in the patient, and lower cost. The benefits include shorter surgery times, reduced blood loss and hence a better patient experience.



BOWA TissueSeal PLUS

The concept of reusability results in maximum cost-effectiveness and is an added incentive to use the BOWA ligation instruments NightKNIFE®, TissueSeal® and LIGATOR®.

BOWA sealing instruments are suitable for a vast range of applications including open and laparoscopic procedures in surgery, gynaecology and urology.

1.9 | ELECTROSURGERY – GENERAL⁽¹⁾

Users should be familiar with the function and use of the devices and instruments (user training in compliance with the Medical Devices Directive / training by the device manufacturer).

1.9.1 | SAFETY PRECAUTIONS TO PREVENT ELECTROSURGICAL COMPLICATIONS⁽¹⁾

- Check the insulation
- Use the lowest effective power setting
- Activation of current flow should be short and intermittent only
- Do not activate while the current circuit is open
- Do not activate near or in direct contact with another HF instrument
- Use bipolar electro-surgery

1.9.2 | NEUTRAL ELECTRODE⁽¹⁾

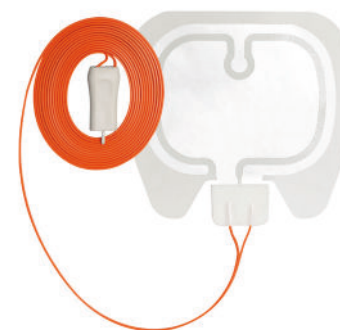
Neutral electrodes are generally supplied as disposable accessories in HF surgery for monopolar applications and are used to close the current circuit between the patient and the HF generator on the passive side.

The main risk associated with improper use of a neutral electrode is localised hyperthermia to the point of skin burns at the contact site and poor HF device function.

These problems can be avoided by using neutral electrodes that are in perfect working order and free of defects. The intended therapeutic application, patient population (adults or children) and patient's body weight must all be taken into consideration and any metal jewellery should be removed in advance.

The site of application of the neutral electrode should be selected such that the current pathways between the active and neutral electrodes are as short as possible and run longitudinally or diagonally to the body, as muscle conductivity is higher along the direction of the fibrils.

Depending on the part of the body undergoing surgery, the neutral electrode should be attached to the nearest upper arm or thigh but not closer than 20 cm to the surgical site and at a sufficient distance from ECG electrodes or any implants (such as bone pins, bone plates or artificial joints). In a supine patient, the neutral electrode must be attached to the upper side of the patient's body to avoid sticking in an area where fluids may collect and flood the device. The electrode should be attached to



BOWA EASY Universal
neutralelectrode

clean, intact and uninjured skin without too much hair growth. Any agents applied to clean the skin should be allowed to dry fully. The electrode must be in full contact with the patient's skin.

Full contact of the neutral electrode with the skin is necessary because the heat generated is proportional to the electrode contact area. EASY neutral electrode monitoring in BOWA generators maximises patient safety by stopping monopolar activation in the event of insufficient skin-electrode contact.

Special care should be taken in patients with pacemakers and implantable cardioverter defibrillators. Follow the manufacturer's instructions and consult the patient's cardiologist if necessary.

There are no reports of adverse events in association with the use of monopolar HF surgery in pregnancy. However, bipolar HF procedures are recommended as a safety precaution.

The neutral electrode should not be removed from its packaging until immediately before use but may be used for up to 7 days after opening if stored in a dry

place at 0 °C to 40 °C. Electrodes are for single use only and must be disposed of thereafter.

1.10 | INTEGRITY OF EQUIPMENT

All devices, cables and other equipment employed should be in perfect working order and checked for defects prior to use.

Check the devices for smooth performance in all the proposed functions and operating modes.

Do not use devices that are defective, contaminated or have been used before.

In the event of device malfunction during treatment, interrupt the power supply immediately to prevent unwanted current flow and possible tissue damage.

Defective devices and instruments should be repaired by qualified personnel only.

If you are not using the foot pedal, keep it at a safe distance to avoid any inadvertent use.

1.11 | NEUROMUSCULAR STIMULATION (NMS)

NMS, or muscular contraction due to electrical stimulation, is a phenomenon observed in electrosurgery in general and monopolar procedures in particular.

Adequate use of muscle relaxants in the patient significantly reduces the incidence of NMS. The benefits include a reduction in the likelihood of accidental thermal damage, the consequences of which may include perforated bowel in procedures associated with that risk.

1.12 | CONTACT WITH CONDUCTIVE OBJECTS

Patients should be adequately protected from contact with conductive objects to prevent unwanted current flow and possible injury.

Patients should therefore be placed on a dry and non-conductive surface.

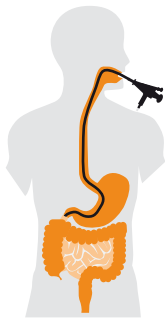Take care to ensure sufficient distance from any metal clips in areas where HF devices (such as snares or APC) are in use.

2

PRACTICE & METHODS

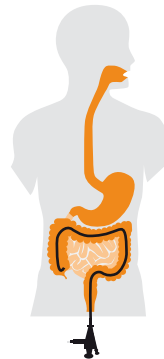
In terms of clinical practice, endoscopy procedures can be divided into two distinct types, with naming conventions depending entirely upon the route of access used, and the location of the organ to be examined.

Procedures involving the upper gastrointestinal, i.e. the oesophagus, stomach and proximal part of the duodenum, are performed by means of a gastroscope inserted through the mouth.



Gastrosocopy

Procedures involving the lower gastrointestinal tract, i.e. the rectum, colon and distal section of the ileum, are performed using a colonoscope inserted through the anus.







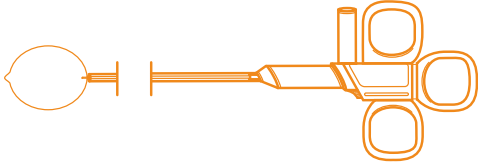


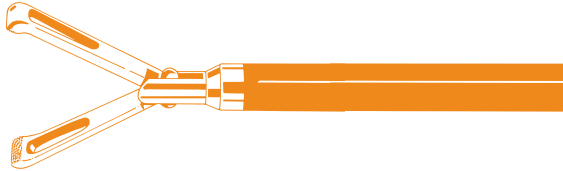
Colonoscopy

procedure requires a specific technique to slowly move the endoscope through the small intestine.

The purpose of all of the procedures described above is to reach the relevant target site. As it is the nature of the condition or disease to be treated that determines which treatment method is used, treatment methods will be discussed in order of symptom presentation.

Double balloon enteroscopy (DBE), also known as push-and-pull enteroscopy (PPE), represents a special endoscopy technique that allows the visual examination of the small intestine. Using an endoscope fitted with an overtube, this

BASIC EQUIPMENT FOR GASTROENTEROLOGY PROCEDURES

<p>APC probe</p> 	<p>BOWA ARC 400 HF generator</p> 
<p>BOWA ARC PLUS</p> 	<p>Endoscope</p> 
<p>Polypectomy snare</p> 	<p>Papillotome</p> 
<p>Needle knife</p> 	<p>Forceps</p> 

2.1 | GASTROINTESTINAL BLEEDING

2.1.1 | ULCER BLEEDING FORREST CLASS IB-IIB

Bleeding represents the most serious complication of a peptic ulcer, and is more significant even than penetration, perforation or gastric outlet obstruction.

An upper gastrointestinal endoscopy, or oesophagogastrroduodenoscopy (OGD), is essential, as there may be several sites of bleeding. These are classified in accordance with the Forrest classification system, and have a clear impact on overall prognosis. Endoscopy procedures are used to reduce the risk of rebleeding, and reduce both the need for surgical interventions as well as patient mortality.

According to findings from prospective, randomised studies, the exact type of

haemostatic therapy used appears to be of secondary importance. What is of crucial importance, however, is that haemostatic therapy should be primarily endoscopic in nature⁽⁷⁾.

Recent research has shown that very good results can be achieved with a combination of APC (argon plasma coagulation) and epinephrine injections⁽⁸⁾.

Endoscopy of the upper part of the small intestine is not contraindicated in patients with suspected penetration or perforation. However, surgical advice should be sought. In these cases, as elsewhere, endoscopy can be used to provide a clear diagnosis, detect concomitant conditions affecting the same area, or identify further complications⁽⁷⁾.

2.1.2 | OESOPHAGEAL VARICES

Oesophageal varices occur as the result of portal hypertension, which can be caused in a number of different ways. Portal hypertension results in the formation of portosystemic collateral veins, which lead to varices in the area of the oesophagus and the gastric fundus⁽⁹⁾.

Approaches to the treatment of oesophageal varices can be divided into acute treatments (where bleeding has occurred), the prevention of bleeding (primary prevention), and the prevention of further bleeding.

ACUTE TREATMENT

Variceal rupture results in bleeding that is potentially life-threatening. The risk of oesophageal haemorrhage is linked to variceal wall tension, variceal diameter and wall thickness, as well as liver function⁽⁹⁾.

Among urgent interventions for acute bleeding, endoscopic therapy (e.g. sclerotherapy (Histoacryl), ligation, oesophageal stenting (Danis stent)) remains the treatment of choice⁽¹⁰⁾.

A Sengstaken-Blakemore tube can be used to buy time if a patient is waiting to undergo endoscopic therapy⁽¹¹⁾.

All patients with acute bleeding need to be moved to intensive care for close monitoring^(10, 12).

Should these measures fail or prove unfeasible, the surgeon may resort to open surgery using the modified Sugiura procedure⁽¹³⁾.

OTHER TYPES OF UPPER GI BLEEDING

Aside from the rupture of oesophageal varices, which occur as a result of portal hypertension, upper GI bleeding can also be caused by

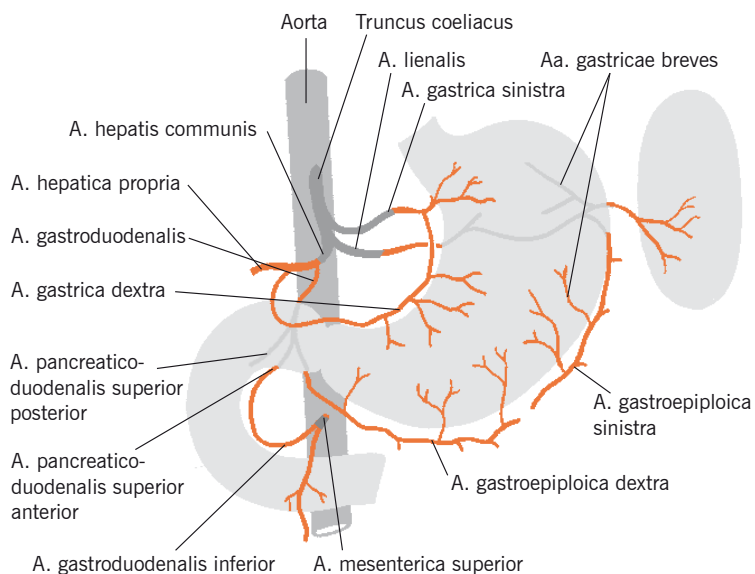
- Peptic ulcers (the most common cause at approximately 35%)
- Oesophageal inflammation
- Medication-induced mucosal lesions
- Trauma-induced or surgery-induced lesions
- Malignant tumours
- Vascular abnormalities
- Duodenal diverticuli

Alternatively, it may be traced back to the hepato-pancreato-biliary system.

Typical symptoms of upper GI bleeding are the regurgitation of blood, or a mixture of stomach contents and blood (haematemesis), and tarry stools (melena). If bleeding is severe, bright red blood may be visible in the stools (haematochezia). If bleeding is slow, the patient may develop non-specific symptoms such as tiredness, lethargy, shortness of breath, or even angina pectoris.

In addition to haemodynamic parameters that provide an indication of the severity of bleeding, there are other symptoms that can help localise the bleeding source or possible concomitant disease:

- Tarry stools and vomiting blood (suggests upper intestinal bleeding)
- Haematochezia (suggests intestinal bleeding or severe haemorrhage distal to the pyloric sphincter)
- Ascites or jaundice (possible bleeding



Anatomical overview of the stomach

from venous collaterals due to cirrhosis of the liver)

2.1.3 | VASCULAR MALFORMATION AND VASCULAR ECTASIA

All patients should be assessed for haemodynamic stability. Where necessary, remedial measures should be taken, and the patient should undergo initial endoscopy.

STOMACH/COLON

Vascular malformation and vascular ectasia (dilation), including GAVE (gastric atral vascular ectasia, or watermelon stomach) and angio-dysplasia, are increasingly being recognised as significant causes of occult gastrointestinal bleeding.

All patients with active bleeding or stigmata of haemorrhage, such as visible vessel or adherent clot, should undergo endoscopic therapy to treat the affected area with, for instance, local argon plasma coagulation (APC) or a number of haemostatic clips.

While APC represents a safe endoscopic treatment method for bleeding in patients with angiodysplasia and GAVE, it is more effective in the treatment of bleeding caused by angiodysplasia.

Adherent clots should be removed using irrigation. If removal is unsuccessful, the area should be injected with suprarenin (to prevent bleeding), and the clot removed with a cold snare polypectomy, followed by endoscopic therapy to treat the underlying lesion.

GAVE patients have higher rebleeding rates, and sometimes need to undergo several procedures before bleeding is successfully stopped⁽¹⁵⁾.

Even among high-risk patients (Forrest class Ia bleeding from an ulcer in the distal duodenal wall), initial haemostasis is achieved in 70 % of patients treated.

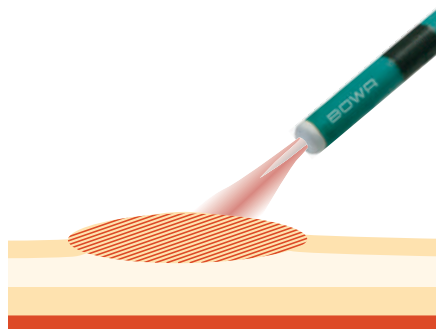
In spite of this, APC remains a safe effective, and economical option for the treatment of patients with GAVE, and represents an alternative to currently-available endoscopy procedures⁽¹⁶⁾.

Endoscopic therapy significantly improves prognosis in terms of the patient's risk of rebleeding, and the need for transfusions or surgery⁽¹⁴⁾.

SMALL BOWEL/RIGHT COLON

Vascular malformation is the most common cause of small bowel bleeding.

The condition can be treated with double-balloon enteroscopy (DBE), using argon plasma coagulation (APC)⁽¹⁷⁾.



Treating surface bleeding with APC

APC procedures using low-energy outputs, such as those which are standard at BOWA, achieve superior results when compared to traditional APC techniques. The lower energy output used allows for more accurate coagulation, and results in improved tissue effects that are virtually independent of application distance. This of course means that the technology can be used to treat angiodysplasia-related bleeding in difficult-to-reach sites such as the caecum or the small bowel.

In terms of efficacy, low-energy APC is comparable to existing methods. However, its improved depth control means it is a safer option that significantly reduces the risk of perforation⁽¹⁸⁾.

2.1.4 | HAEMOSTASIS/COAGULATION – APC

Nowadays, APC is used widely in the treatment of non-variceal bleeding in both the upper and lower gastrointestinal tracts. Conditions that can be treated with this technology range from bleeding ulcers, angiodysplasias, and Dieulafoy's lesions to instances of bleeding that are associated with benign and malignant tumours. Aside from the fact that APC is simple to use, safe, and associated with very few side effects, there are hardly any instances where it cannot be used. While APC is certainly not intended as a primary treatment method in patients with ulcer bleeding, it can reduce the need for transfusions in patients with GAVE (watermelon stomach). The same also applies to radiation colitis⁽¹⁹⁾.

The term radiation-induced procto-sigmoiditis refers to a serious complication of pelvic radiation therapy, a radiation treatment that is delivered as part of treatment for pelvic malignancies, and is often associated with rectal bleeding. Drug-based treatment is generally insufficient, while surgical measures are associated with high morbidity and mortality. In these cases, APC not only represents a simple-to-use, safe and effective method of treating haemorrhagic, radiation-induced procto-sigmoiditis^(20–22), it has also proven to be better than other treatment methods, including hyperbaric oxygen therapy⁽²³⁾.

When used in the treatment of radiation-induced proctocolitis, APC has been shown to result in significantly reduced levels bacteraemia that do not warrant antibiotic prophylaxis⁽²⁴⁾.

At optimal settings, APC has a high success rate, and achieves long periods of remission without significant complications⁽²⁵⁾. In addition to this, the sheer extent of clinical data available on APC, and the fact that it is widely available, mean that it is the preferred choice for first-line therapy⁽²⁶⁾.

In patients with radiation-induced gastritis, a serious complication of radiation therapy for pancreatic cancer, endoscopic therapy using APC can lead to considerable improvements in the severity of anaemia, which in turn means that patients do not require any further blood transfusions⁽²⁷⁾.

2.2 | NEOPLASMS

2.2.1 | BARRETT'S OESOPHAGUS

Worldwide, Barrett's oesophagus (BE) is one of the most common pre-cancerous conditions, and its incidence is increasing⁽²⁸⁾.

Barrett's oesophagus can develop as a result of long-term, chronic reflux disease. Over time, continued acid exposure will lead to changes (from metaplasia to malignant growth) in the mucosal lining of the oesophagus. These changes include the replacement of the normal squamous epithelium of the oesophagus with columnar epithelium, while the demarcation line between the two is displaced into the

oesophagus. Ulcers are common in this area⁽⁹⁾.

Macroscopically, severity of the condition is classified using the Prague C&M Criteria, which take into account the length and circumference of the segment that reaches into the oesophagus (>3 cm = long-segment Barrett's oesophagus (LSB), <3 cm = short-segment Barrett's oesophagus (SSB)). Histologically, the severity of the changes at the demarcation line between squamous epithelium and columnar epithelium, which is situated above the gastro-oesophageal junction, is graded according to the presence of low-grade (LGIN) or high-grade (HGIN) intraepithelial neoplasia^(29–31).

Endoscopic mucosal resection (EMR) is recommended as a diagnostic intervention in patients with visibly elevated LGIN⁽³²⁾.

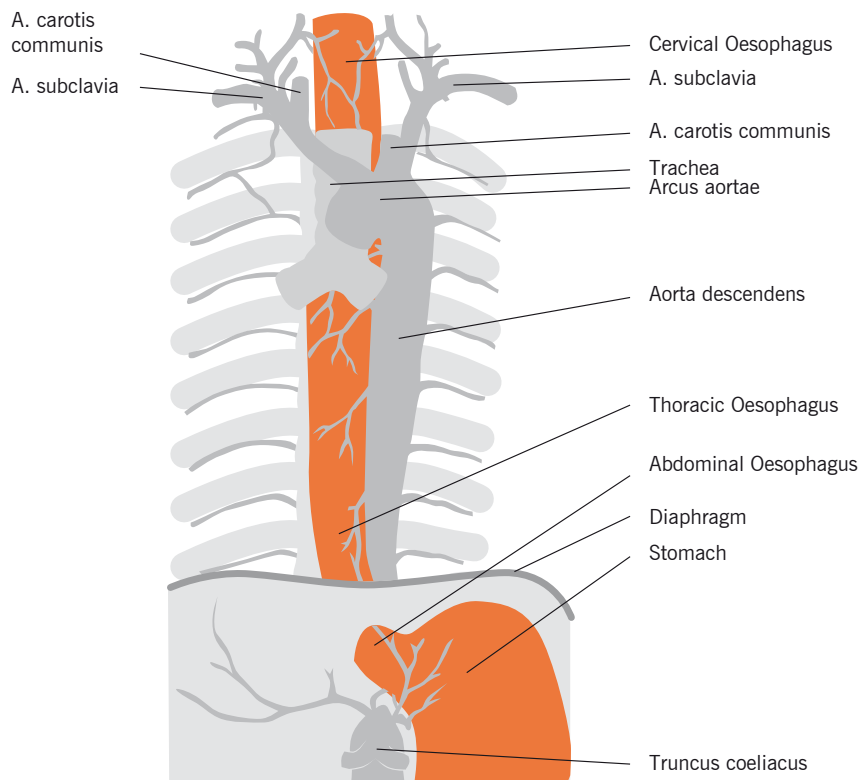
The presence of high-grade intraepithelial neoplasia (HGIN) is associated with macroscopically invisible cancerous lesions in approximately 40% of cases. As a result of the resultant level of uncertainty, and because of an increased risk of cancer, EMR is recommended in patients with HGIN and early cancer⁽³¹⁾.

2.2.2 | OESOPHAGEAL CANCER AND BARRETT'S CANCER

Oesophageal adenocarcinoma (Barrett's cancer) must be virtually unique among malignant diseases in terms of the sheer extent of developments that have been seen in the fields of epidemiology, diagnosis and treatment over the past decade. While still classed as having a particularly poor prognosis by the textbooks available to the previous generation of physicians, it is now regarded as a form of cancer that is immensely treatable in its early stages⁽³³⁾.

The term oesophageal carcinoma refers to malignant growths that are epithelial in origin, and which can be divided into squamous cell carcinomas (75%) and adenocarcinomas.

Barrett's cancer is an adenocarcinoma involving the distal oesophagus, which is not always easy to distinguish from a stomach tumour that originates in the cardia⁽⁹⁾.



Anatomical overview of the oesophagus

Curative use of EMR is the current gold standard for the local treatment of early-stage Barret's cancer (pT1m, L0, V0, G1/2) in Germany. Endoscopic submucosal dissection has so far failed to become established in Europe^(33, 34).

As tumours of category T1b (submucosal involvement) onwards are associated with an increased risk of lymph node involvement, endoscopic therapy is only recommended in cases where surgery is not an option⁽³⁵⁾.

Both methods involve the complete resection and histological analysis of the mucosa and the submucosa. Currently, evidence of HGIN is the only histological risk factor for the development of this type of adenocarcinoma⁽³⁰⁾.

If histological analysis of the resected tissue reveals a mucosal carcinoma that is not associated with additional risk factors (no invasion of the lymph vessels, no vein involvement, and radical R0 resection), the patient is treated with curative intent,

and requires regular follow-up endoscopies. Patients with evidence of submucosal infiltration and/or involvement of the lymph vessels or veins, should undergo oesophageal resection⁽³³⁾.

2.2.3 | BENIGN OESOPHAGEAL TUMOURS

Benign oesophageal tumours are far less common than malignant ones. The majority of these are of mesenchymal origin (e. g. GIST, leiomyoma, fibroma, lipoma, haemangioma, myxoma), while tumours of epithelial origin (cysts, papillomas) are much less common.

Currently, endoscopic submucosal dissection (ESD) is regarded as the main choice of treatment in patient with superficial tumours of the gastrointestinal tract (including the oesophagus) that are up to 4 cm in diameter. In the case of larger tumours, surgical resection remains the only option. One of the advantages of ESD is that it is effective at removing lesions regardless of their size and the severity of fibrosis pre-

sent. Due to very good results in patients with oesophageal tumours with a low risk of lymphatic metastases, an increasing number of patients are now able to benefit from ESD.

However, due to the complexity of the technology, ESD requires experienced practitioners. In order to prevent complications (perforation, postoperative gastric outlet obstruction), patient selection for ESD should follow very narrowly-defined criteria^(9, 36).

2.2.4 | GASTRIC ADENOCARCINOMAS

Gastric cancers are malignant neoplasm arising from the gastric epithelium⁽⁹⁾. Helicobacter pylori-induced gastritis represents the most important risk factor for gastric cancers involving the corpus or antrum. Other risk factors include chronic autoimmune atrophic gastritis, prior partial resection of the stomach, adenomatous polyps, Ménétrier's disease, as well as diet and genetic factors⁽³⁷⁾.

The Western world continues to regard a subtotal or total gastrectomy as the standard treatment in patients diagnosed with early gastric cancers. The aim of treatment is the complete removal of the primary tumour and any regional lymph nodes that may be affected by the disease. In Japan, the treatment of choice in patients with early gastric cancers confined to the mucosa is endoscopic mucosal resection (EMR), a treatment method that is now beginning to gain wider acceptance in Europe⁽³⁸⁾.

Local endoscopic resection with curative intent is indicated in patients who fulfil the standard criteria: tumour is confined to the mucosal layer; tumour measures less than 2 cm; upon macroscopical examination tumour is polypoid (type I), elevated (type IIa), flat (type IIb) or depressed (type IIc); tumour is well or moderately well differentiated (G1/G2).

Local endoscopic therapy is associated with low morbidity and causes no reduction in the patient's quality of life. It therefore provides a superior choice when compared with surgery, particularly in older patients and patients with considerable comorbidities^(39, 40).

EMR usually involves four different techniques:

1. Submucosal injection followed by resection
2. Submucosal injection, followed by lifting and resection
3. Cap-assisted resection (EMR-C)
4. EMR with ligation (EMR-L)

Polypoid lesions should be removed using a polypectomy snare, and after submucosal injection. In the case of flat lesions, the recommendation is to use the same injection-assisted method as for polypoid lesions, or ‘cup-assisted resection’ with either cup-assisted or ligation-assisted techniques. At the start of the procedure, the exact area to be resected has to be identified and measured, and then marked around its margin, for instance using coagulation. The limitation of this procedure is the fact that only lesions of up to 2 cm can be resected in one piece. Tumour recurrence is particularly common in cases where en bloc resection of the original tumour proves impossible⁽³⁸⁾.

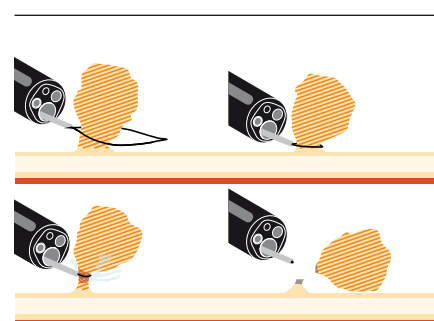
APC appears to be a safe and beneficial treatment option in patients with early gastric neoplasms and a high risk of severe complications – irrespective of the level of experience of the physician performing the procedure⁽⁴¹⁾.

Curative local therapy should only be performed in centres with a sufficient level of experience/number of procedures, particularly in patients who meet the extended criteria^(38, 42, 43).

2.3 | RESECTION

2.3.1 | POLYPECTOMY

Polyps are macroscopically visible projections above the mucosal layer that are usually attached by a stalk. Only histological analysis is capable of determining whether they are benign or malignant. This is why polyps should be harvested individually and their exact location recorded⁽⁴⁴⁾.



Endoscopic polypectomy

Approximately 80% colorectal cancers (CRC) develop from adenomatous polyps. On average, it takes 10 years for a polyp to develop into an invasive CRC. Colonoscopic polypectomy procedures reduce the incidence of CRC by up to 90%⁽⁴⁵⁾.

The first endoscopic procedure to remove colonic polyps using a flexible device was performed 40 years ago at the University of Erlangen, Germany. This very procedure laid the foundations for the use of colonoscopy in the prevention of cancer⁽⁴⁶⁾.

	DIFFICULT POLYP	TIP	
Morphology	Sessile	Submucosal injection	
Size and shape	> 10 mm	Resection in one piece (except caecum)	
	< 15 mm	Diluted epinephrine, piecemeal resection, EMR or ESD	
	Large (> 30 mm), on fold, carpet-like, lobular or serrated	APC	
	Large head	Inject diluted epinephrine into head	
	Pedunculated (if large)	Endoclips/endoloops	
	Thick pedicle		
Total number	Multiple polyps	Harvest individual polyps and send to histology	
Localisation/positioning	Right colon, caecum	Do not use hot biopsy forceps	
	Situated behind folds	Start with injection at distal margin	
	Endoscope difficult to position		Change to 5 o'clock position
			Change patient's position
			Abdominal pressure
			Spasmolytics (e.g. butylscopolamine)
			Use air aspiration prior to grasping the polyp
	Resection on forward movement: small polyp, Resection on backwards movement: large polyp		
Increased colon motility	Mark polyp position with ink		

The decision as to whether a patient needs to undergo endoscopic polypectomy depends on the nature and extent of their clinical symptoms (occult blood or visible bleeding, occlusion) and/or the need for early cancer screening and cancer prevention^(47, 48).

Polypectomy is a pain-free procedure that involves the use of electronic forceps or an electronic snare. Once inserted through an endoscope, these tools can be used for a number of different techniques, or for endoscopic mucosal resection (EMR). Selection of the technique to be used depends on the type of polyp involved. All techniques involve cauterisation of the site of polypectomy to prevent bleeding.

Nine steps need to be followed for successful polypectomy⁽⁴⁹⁾

1. Locate the polyp
2. Analyse polyp's shape
3. Determine polyp's size
4. Analyse polyp's surface
5. Determine total number of polyps
6. Position the polyp before commencing resection
7. Determine resectability using endoscopic methods
8. Use submucosal injection (injection-assisted polypectomy)
9. Appropriate skill level regarding the use of clips and/or endoloops

The aim of every procedure should be the complete removal of a polyp. This is essential as remaining sections could contain evidence of high-grade intraepithelial neoplasia or cancer⁽⁴⁴⁾. For this reason, a standardised procedure should be followed⁽⁴⁹⁾:

Polyps <5 mm should be resected completely using forceps. If using hot biopsy forceps, the polyp should be lifted as far from the colon wall as possible prior to starting coagulation⁽⁴⁴⁾.

Polyps >5 mm should be resected completely using endoscopic snare excision. The use of endoscopic snare excision for the removal of large polyps is contingent upon, as well as limited by, whether complete resection is likely, and whether this can be achieved with a low risk of bleeding or perforation⁽⁴⁴⁾.

Alternative methods for the removal of

polyps (open surgery or laparoscopic resection, rendezvous procedures, TEM, transnasal resection) should be considered in certain cases.

Endoscopic submucosal dissection (ESD) for en bloc resection of polyps is currently undergoing testing, with a number of questions remaining unanswered.

DIFFICULT POLYPS

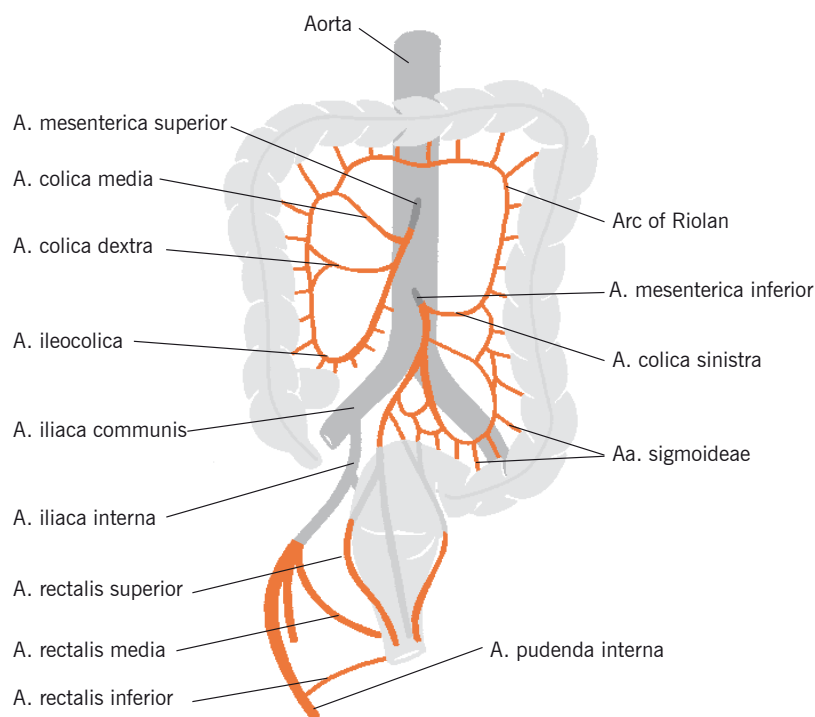
The term difficult polyp refers to any change in colonic mucosa that is flat or elevated in shape, and which is difficult to remove as a result of its size, shape or location, but also refers to the total number of polyps present, as the risk of complications increases in line with the number and complexity of polypectomies.

There are nine important steps need to be followed to ensure successful resection of a colon polyp, particularly in the case of difficult polyps:

1. Locating the polyp: as the walls of the caecum, the ascending colon, and descending colon are much thinner than elsewhere, polypectomies in these

areas are associated with the highest levels of risk. Over-insufflation with air should therefore be avoided during resection. This will reduce wall tension, and result in the polyp becoming easier to grasp/snare. Due to its high degree of vascularisation, the rectum is particularly prone to bleeding following resection.

2. Once the snare has been placed around the polyp, the device should be kept at an appropriate distance from surrounding tissue. It is also important to minimise any pressure exerted on the wall of the colon in order to ensure that the HF current can pass safely across the base of the polyp.
3. Submucosal injections should be used on all polyps situated on the surface of folds, larger polyps situated between two folds, and polyps that extend across two folds, in order to prevent deep lesions or perforations. In the case of larger polyps (>15 mm), it may be preferable to use piecemeal mucosal resection or endoscopic submucosal dissection (ESD).



Anatomical overview of the colon

4. Great care should be taken when treating polyps >20mm, particularly if dealing with flat or sessile polyps. Treatment should follow submucosal injection, as this technique increases the chances of complete resection down to healthy tissue. In the case of pedunculated polyps, resection technique is mainly determined by polyp shape (thin, thick, short, or long). However, polyp removal should also aim to be complete and down to healthy tissue⁽⁴⁹⁾.
5. The first EMR procedure is an important predictor of outcome in patients with sessile colorectal polyps sized 20mm or larger, with previous attempts representing a significant risk factor in terms of the procedure's overall efficacy. In spite of this, endoscopic therapy remains a safe and effective option in the treatment of sessile colon polyps, and allows the detection of lesions that are at increased risk of submucosal abnormalities⁽⁵⁰⁾.
6. Ulcerated polyps and polyps that have abnormal tissue or vascular patterns should not be resected, unless the procedure is aimed at debulking.
7. Macroscopically, there is no clear evidence of malignant changes.
8. A polyp's positioning may make its removal difficult. The endoscope should therefore be moved to the 5–6 o'clock position, to allow easier positioning of the different devices (e.g. snare). For this, the endoscope's shaft should remain straight, and an additional person may be needed to hold it to prevent the tip from twisting. Polyp removal during retraction, pressure on the patient's abdomen, and altering the patient's position can all have a positive impact on the outcome of a resection procedure. In rare cases, successful resection of a difficult-to-reach polyp can be achieved with retroflexion, the use of a gastroscope, or the use of the double-scope technique.
9. If multiple polyps are present, not more than 10 polyps should be removed in a single session, and each polyp should be harvested individually, and sent for histological analysis.

Submucosal injection – this procedure should be used in all sessile polyps >15mm in diameter. Generally speaking, this technique is suitable for all polypectomy procedures, with its use allowing for greater distance between base and serosa, thus reducing the risk of perforation, bleeding and thermal injury to the gut wall.

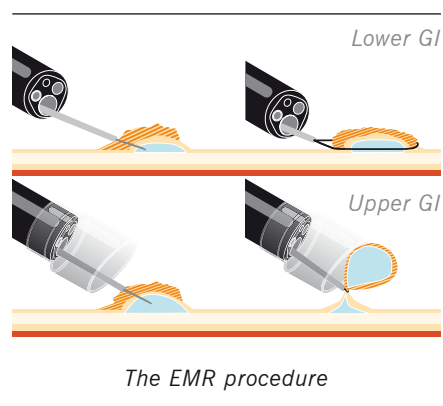
Possible injection fluids are saline, a 50% dextrose with saline solution, saline with methylene blue, sodium hyaluronate, fibrinogen and hydroxypropyl methylcellulose (HPMC), or a mixture of saline and epinephrine (1:10.000). Injection solutions containing epinephrine must not be used in the caecum due to the risk of inducing ischaemic colitis.

In the case of polyps with a large head, the epinephrine mix can be used to reduce the head's size prior to removal (Hogan technique). Doing so will also reduce bleeding during resection.

Where complete resection proves impossible, APC can be used to treat any remaining sections, either as part of the same or a subsequent session. The power setting for APC should be between 20W (caecum) and 60W (descending colon, rectum)⁽⁴⁹⁾.

2.3.2 | ENDOSCOPIC MUCOSAL RESECTION (EMR)

EMR is an endoscopic procedure that is used to remove an organ's mucosal layer, for instance in cases where the complete removal of a tumour is required to cure malignant disease.



Endoscopic mucosal resection (EMR) can be used to resection flat lesions. Lesions

that are completely depressed should generally be treated surgically, not endoscopically. As the majority of such lesions are beyond the T1 stage of early invasive cancers, radical endoscopic resection (RO) is very rare. One indication of this is failure of the polyp to lift away from the colon wall (non-lifting sign)⁽⁴⁴⁾.

By definition, every polypectomy procedure is a mucosal resection because the main aim of the procedure is to remove the lesion in its entirety. The rate of en bloc resections is higher for pedunculated polyps than for sessile or flat polyps.

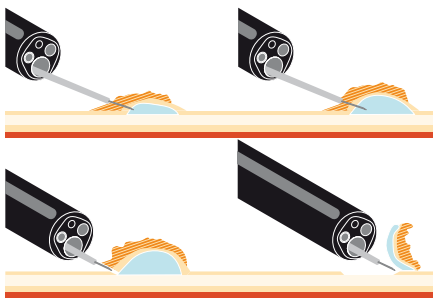
EMR makes it possible for the polypectomy procedure to include enough of the tissue surrounding the the neoplasm. Results can be further improved by submucosal injection, a technique that prevents undesirable effects on the surrounding tissue when using APC or HF currents⁽⁴⁹⁾.

2.3.3 | ENDOSCOPIC SUBMUCOSAL DISSECTION (ESD)

ESD is a modification of EMR, and represents a new technique for the resection of superficial neoplastic lesions of the gastrointestinal tract that also allows the en bloc resection of large early gastric cancers. Although originally developed for use inside the stomach, the technology's current primary use is for colorectal procedures. The advantages of en bloc resection are improved healing and improved histological diagnosis, which can have a critical impact on the patient's individualized treatment regimen.

When ESD is used in the gastric area, the risk of perforation is greatest in the upper section of the stomach. An increase in the length of the procedure is associated with a slight increase in the risk of bleeding, which is also seen in patients aged >80 years⁽⁵¹⁾.

In Europe, areas of application remain limited to procedures involving the caecum and the ascending colon.



The ESD procedure

In terms of technological differences, the main distinguishing feature between ESD on the one hand, and polypectomy and EMR on the other, is the use of a distal attachment (cap), and the use of various different knives and haemostatic devices^(49, 52).

2.3.4 | PIECEMEAL POLYPECTOMY

The most important feature of piecemeal polypectomy is the generous use of the submucosal injection technique, which ensures a sufficient distance between the mucosa and deeper tissue layers.

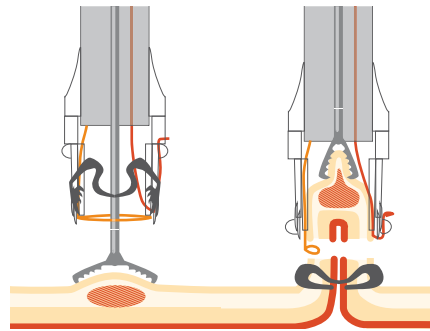
There are no specific recommendations in relation to piecemeal polypectomy. The procedure is recommended for the treatment of sessile or flat polyps >20 mm. Resection should be started at the proximal end of the polyp, and finish at the distal end. For very large polyps, there are no firm and fast rules as to the number of sections of the polyp that can be removed in one session. Sessile, flat and laterally-spreading polyps between 15 mm and 25 mm in diameter can usually be resected as two or three separate pieces⁽⁴⁹⁾.

Following piecemeal resection, small areas of neoplastic tissue may remain along the resection margin. As this is far from a rare occurrence, a treatment optimisation strategy involves submucosal injection followed by APC immediately after polypectomy, or shortly thereafter^(19, 54).

2.3.5 | ENDOSCOPIC FULL-THICKNESS RESECTION

A new technique was developed to deal with cases involving the colon and rectum and requiring endoscopic full-thickness resection (EFTR) of neoplastic lesions (for

instance broad-based adenomas, early cancers, repeat resections necessary to achieve a clear resection margin, endoscopic mucosal resection (EMR), or endoscopic submucosal dissection (ESD)⁽⁵³⁾.



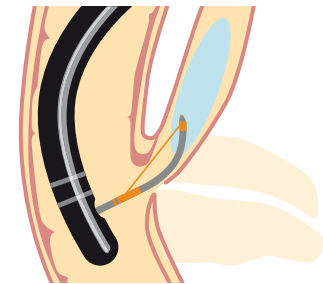
The EFTR procedure

The technique combines a clip-based electroresection procedure for full-thickness resection with a procedure for the collection of tissue samples. It is based on the OTSC (Over-the-Scope Clip) system and, when used on suitable lesions of the colon and rectum, allows the removal of all of the layers of the gastrointestinal wall, including the serosa. The design of the endoscopic full-thickness resection system ensures that transection of the bowel wall only occurs once a secure seal has been established around its base. As a result, the device never enters the abdominal cavity, thus minimising the risk of complications from peritonitis following the procedure.

2.4 | INCISION

2.4.1 | PAPILOTOMY

The term papillotomy refers to a procedure that is performed during endoscopic retrograde cholangiopancreatography (ERCP), and is used to gain access to the bile and pancreatic ducts. The procedure involves the partial or complete division of the sphincter situated on the major duodenal papilla/hepatopancreatic ampulla, and provides access for other endoscopic procedures, such as the removal of gall stones. Trauma to the pancreatic duct should be kept to a minimum, as post-ERCP pancreatitis is a much-feared complication of the procedure and is to be avoided at all cost⁽⁵⁵⁾.



The papillotomy procedure

When locating the bile duct/pancreatic duct, the papillary orifice should be examined and monitored for possible biliary secretions. Cannulation will usually involve the use of a catheter or a papillotome. Increasingly, this procedure is performed using a papillotome with guide wire. This is because purely diagnostic ERCP procedures are gradually becoming less common, and because a papillotome can be used to prepare subsequent treatment steps⁽⁵⁵⁾. Visualisation of the common bile duct is also possible, and is achieved by injecting a contrast agent. Pre-cut papillotomy offers an alternative in cases where cannulation proves unsuccessful.

PRE-CUT PAPILOTOMY USING A PRE-CUT PAPILOTOME OR NEEDLE KNIFE

The term pre-cut papillotomy refers to a procedure that is used to create an opening in the papillary roof, which allows easier identification of the relevant ducts, and is used when cannulation of the biliary duct/pancreatic duct, has proved unsuccessful.

The needle knife facilitates difficult cannulation, and remains the surgeon's first choice for such procedures.

The advantage of a pre-cut papillotome, in particular if it is a twistable model, is that its tip is easier to position on the papilla. This means that in complex cases the device can be used to assist with manipulation. Use of a guide wire improves accuracy, and makes it easier to identify the relevant duct without the need to resort to a contrast agent⁽⁵⁵⁾. When performed with a pre-cut papillotome and a soft guide wire, the procedure is safe and effective in patients with difficult-to-access bile ducts, where conventional sphincterotomy or needle knife papillotomy have failed⁽⁵⁶⁾.

2.4.3 | ACHALASIA

Achalasia is a muscular motility disorder, in which the muscles of the lower part of the oesophagus (oesophageal sphincter) no longer function properly.

Achalasia can be divided into three stages, with a gradual worsening of symptoms associated with each stage (I through III).

- Stage I – hypermotile form (hypermotile = overactive)
The oesophagus continues to function, producing high-pressure waves to overcome the excessive pressure in the lower oesophageal sphincter.
- Stage II – hypomotile form (also referred to as ‘bird beak’ appearance)
The muscles of the oesophagus start to lose tone, and the oesophagus becomes increasingly dilated.
- Stage III – amotile form (amotile = non-moving)
End-stage achalasia. The oesophagus has effectively become a tube of limp muscle that is ‘suspended’ within the mediastinum. The oesophagus is dysfunctional and is completely amotile.

TREATMENT OPTIONS:

Balloon dilation

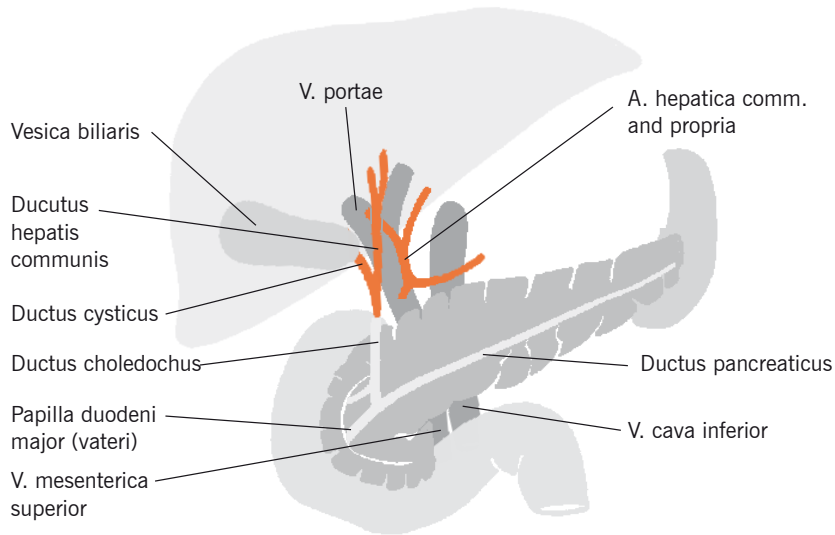
A balloon catheter is used to physically dilate (balloon dilation) the lower oesophageal sphincter, tearing the muscle of the lower oesophageal sphincter, thus making it possible once more for food to pass into the stomach. The procedure is usually pain-free, as it is performed as part of a gastroscopy, and under sedation.

Surgical treatment options

A surgical treatment option that is becoming increasingly more common is Heller’s myotomy, a laparoscopic procedure that can achieve the permanent relief of symptoms.

POEM

A new technique for the treatment of swallowing disorders (in particular achalasia) that is available now is ‘per-oral endoscopic myotomy’ (POEM)^(62, 63).



Anatomical overview of the pancreas and its surroundings

2.4.2 | ZENKER'S DIVERTICULUM

Zenker’s diverticulum is an outpouching at the posterior wall of the hypopharynx that forms a large false diverticulum. It is the most common type of oesophageal diverticulum, and mainly affects older men. Zenker’s diverticulum develops in the posterior part of the Killian triangle, usually on the left, and close to the upper oesophageal sphincter⁽³⁷⁾.

Treatment options for Zenker’s diverticulum include open surgery, as well as endoscopic procedures with a rigid or flexible endoscope.

Endoscopic procedures involve the surgical sectioning of the cricopharyngeus muscle (cricopharyngeal myotomy) which, during the endoscopy procedure, appears as a septum between the oesophageal lumen and the diverticulum.

Flexible endoscopic therapy has proved particularly useful in the treatment of older patients with multiple comorbidities, as the procedure does not usually require patients to be intubated for anaesthesia. Treatment usually involves a minimally-invasive procedure, results in low recurrence and complication rates, and is

generally provided on an outpatient basis, or involves only a short stay in hospital. Oesophageal perforation is the most common complication to occur during the procedure^(57–59).

While the majority of authors recommend the use of flexible endoscopy be limited to patients with multiple comorbidities, the procedure is becoming increasingly more common among all symptomatic patients. Several case series have demonstrated flexible endoscopy procedures to be both safe and effective⁽⁵⁸⁾.

There are two main options when performing cricopharyngeal myotomy:

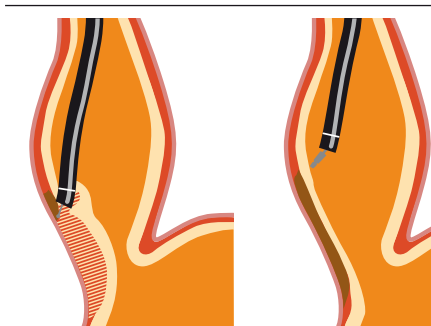
NEEDLE KNIFE PAPILOTOMY:

Needle knife papillotomy has proven track record even in severely ill patients⁽⁶⁰⁾.

ARGON PLASMA COAGULATION (APC):

If equivalent results are to be achieved, patients will require an average of 2–3 sessions. However, the early ignition-feature of the ARC Plus series further reduces the risk of oesophageal perforation⁽⁶¹⁾.

According to currently available data, none of these treatments can be regarded as being intrinsically better than the rest⁽⁵⁸⁾.



The POEM procedure

The procedure involves the creation of a submucosal tunnel in the distal oesophagus, which is then used to cut the inner circular muscle in order to remove the cause of the narrowing. The opening in the oesophagus is then closed using endoscopic closure techniques. The procedure results in normal swallowing being restored.

2.5 | TUMOUR DEBULKING¹ AND ABLATION

2.5.1 | TISSUE NECROSIS – APC

Both tissue necrosis and shrinkage achieved through APC are used in the treatment of tumours and obstructive tissue. In early-stage tumours, where the desired effect is the destruction of tissue, the overall effect can be enhanced through the mechanical removal of tissue.

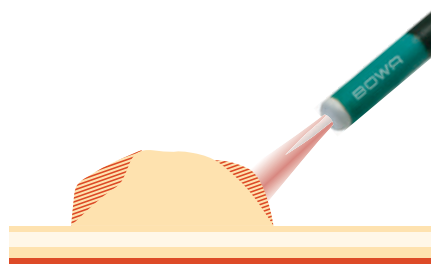
The technology can also be used to coagulate and desiccate tissues in cases of obstruction caused by excess or swollen tissue, or where the cancer is untreatable. If used at higher outputs, the technology can also be used to achieve thermal carbonisation and/or vaporisation.

In the field of gastroenterology, this technology can therefore be used for the treatment of malignant tumours and metastases⁽⁶⁵⁾.

2.5.2 | TREATING TUMOURS – APC

Treatment strategies depend upon both the size and location of the tumour, as well as other relevant factors, and can involve either its removal or gradual reduction in size. Both strategies can make use of several different options.

In the right colon, where the colonic wall is thin, a power setting of 40W should not be exceeded⁽¹⁹⁾.



APC for tumour

APC is mainly used for the palliative treatment of patients with larger tumours of the oesophagus, stomach, or rectum. (The generator must be used on its maximum setting in order to achieve sufficient ablation.)⁽¹⁹⁾

As BOWA HF generators require only low energy outputs for both ignition and treatment, excellent results can be achieved even at low energy outputs of between 5–10 W^(66, 67).

SMALL TUMOURS <15 MM

APC can be used for the curative treatment of smaller malignant tumours/early-stage cancers. For this, the Argon Flexible mode should be selected, as the Argon Pulsed mode cannot guarantee accurate targeting of the tumour, and is therefore associated with a higher risk of causing tissue necrosis in surrounding tissues. For treatment optimisation, APC can also be used in combination with EMR or photodynamic therapy (PDT), for which it used at a power setting of between 80 and 90 W⁽¹⁹⁾.

LARGE TUMOURS >15 MM

The combination of APC and high-dose-rate (HDR) brachytherapy can be more effective in the palliative treatment of patients with inoperable oesophageal cancer than APC alone. It also results in fewer complications and an improved quality of life when compared with either APC alone or different combinations of treatments⁽⁶⁸⁾.

The Argon Pulsed mode should be selected for this purpose. Effect setting 1 can be used by the inexperienced physician or when conditions are particularly difficult,

while effect settings 2 and 3 are suitable if working at a faster pace. Power output is usually between 60 W and 80 W. When treating large tumours, several sessions may be necessary to kill and ablate all of the affected tissue.

2.5.3 | RECANALISATION OF STRICTURES/STENOSES

Argon-plasma-coagulation (APC) or self-expanding metal stents (SEMS) can be used to restore swallowing in patients with gastro-oesophageal stricture due to adenocarcinoma⁽⁶⁹⁾.

In patients with complete bowel obstruction due to cancer or metastatic disease, and requiring debulking, APC can be used in place of high-risk emergency surgery to decompress the bowel⁽⁷⁰⁾. APC can prove successful in certain cases where other treatment methods, such as balloon dilation and bougie dilatation, have failed and may therefore be taken into consideration as a potential treatment option⁽⁷¹⁾.

2.6 | ADDITIONAL PROCEDURES

2.6.1 | OESOPHAGUS – MISCELLANEOUS

HETEROTOPIC GASTRIC MUCOSA (HGM) OR 'CERVICAL INLET PATCH':

A cervical inlet patch is a congenital tissue anomaly that consists of ectopic gastric mucosa at the level of, or just distal to the upper oesophageal sphincter.

The majority of patients with cervical inlet patch are asymptomatic.

Symptomatic patients report instances of acid-related complications such as oesophagitis, ulcers, and strictures. These should not be overlooked during endoscopy^(72, 73).

APC treatment has been shown to eradicate symptoms, and achieves improvements in globus sensation^(74, 75).

2.6.2 | STOMACH – MISCELLANEOUS

OESOPHAGEAL LEIOMYOMA (EL) AND GASTROINTESTINAL STROMAL TUMOUR (GIST):

Leiomyoma is a benign smooth muscle tumour, and belongs to the group of benign

¹ Achieving a reduction in the size of the tumour using surgery, radiation, chemotherapy drugs, devascularisation or regional hyperthermia⁽⁶⁴⁾

mesenchymal tumours. These tumours are ubiquitous, and are found in all organs that contain smooth muscle.

Endoscopic dissection is problem-free in tumours with a diameter of up to 5 cm. The procedure does not result in major bleeding or perforation. Endoscopic therapy is associated with shorter periods of hospitalization and lower treatment costs when compared with conventional methods of treatment⁽⁷⁶⁾.

DUMPING SYNDROME AFTER ROUX-EN-Y GASTRIC BYPASS SURGERY:

Dumping syndrome is a well-recognised complication of Roux-en-Y gastric bypass surgery. The condition can be chronic, and is characterised by the rapid emptying (dumping) of stomach contents into

the small bowel. The 'early' form of the condition (10–20 minutes after eating) is associated with a variety of symptoms, including for instance nausea, dizziness, tachycardia, and even low blood pressure and hypovolaemia. The 'late' form of the condition is associated with symptoms typical of hypoglycaemia⁽⁷⁷⁾.

Treatment involves a combination of argon plasma coagulation, endoscopic suturing and fibrin glue, has a low complication rate, and can leave patients permanently free of symptoms⁽⁷⁸⁾.

CHRONIC GASTRO-OESOPHAGEAL REFLUX DISEASE (GORD)

Gastro-oesophageal reflux disease (GORD) is caused by a failure of the lower oesophageal sphincter, resulting in the reflux

of stomach contents into the oesophagus. Consequences of the condition can range from a significant reduction in the patient's quality of life to an increased risk of adverse health effects (such as ulceration, Barrett's oesophagus, and the aspiration of stomach contents)⁽³⁷⁾.

This is why the symptom index threshold for exploratory endoscopy should be set at a low level.










This particularly applies to patients with 'red flag' symptoms (dysphagia, signs of bleeding, and weight loss), who should be referred for urgent endoscopy. An exploratory endoscopy allows pre-malignant and malignant changes to be detected early, and offers the option of organ preservation through local endoscopic therapy⁽⁷⁹⁾.















3


OVERVIEW OF RECOMMENDED SETTINGS

Recommended settings for the various devices can be found in the table below. These may need to be adapted in line with the clinical situation and the specifications provided in the relevant professional guidelines. Please ensure professional guidelines are adhered to at all times.

RECOMMENDED SETTINGS FOR GASTROENTEROLOGY*

PROCEDURE	INDICATION	TECHNOLOGY	INSTRUMENT	MODE	SETTING	APPLICATION	NOTES	
POLYPECTOMY	Polyps <5 mm		Hot Biopsy forceps		GastroCOAG	10–30 W	Injection needle: while injection if necessary with lower power/effect setting	
	Polyps >5 mm	Pre coagulation	HF Snare		GastroCOAG	10–30 W	Right colon: start with rather lower effect and power setting	
		Ablation			GastroLOOP	Effect 2–4	Entire gastro-intestinal tract	Large flat polyp: monofile snare or band snare recommended
				Effect 3–5				
Pedicated polyp								
PIECEMEAL-POLYPECTOMY	Difficult polyp, large flat polyp							
ERCP	Representation of the bile ducts, gallbladder and the pancreatic duct with X-ray contrast agent, Gallstone removal	Papillotomy	Knife- / Needle- / Papillotome		GastroKNIFE	Effect 2–4	Ductus choledochus	Difficult cannulation: Guidewire, needle papillotome
		Precut Maneuver	Precut-Papillotome				Ductus pancreaticus	
BIOPSY	Removal of small colonic polyps		Hot Biopsy forceps		GastroCOAG	10–30 W	Removal of histology slides in the non-active mode	

PROCEDURE	INDICATION	TECHNOLOGY	INSTRUMENT	MODE	SETTING	APPLICATION	NOTES		
ELECTROTOMY	Zenker diverticulum POEM		Needle instrument	 medium	GastroKNIFE	Effect 2–5			
			APC Probe	 Argon flexible	Argon flexible	30–60 W			
				 Pulsed 4.4kV	Arg. flexible pulse	Effect 1–3, 30–80 W			
EMR	Polyps		HF Snare/ caps resection snares	 fast	GastroLOOP	Effect 2–5	Entire gastro-intestinal tract	Injection needle: while injection if necessary with lower power/effect setting	
			Haemostasis	APC Probe	see APC				
			Marking	APC Probe	see APC				
				Needle instrument	 GastroCOAG	GastroCOAG			10–30 W
			Incision	Needle instrument	 medium	GastroKNIFE			Effect 2–5
ESD	Benign tumors <4–5 cm difficult polyps		Marking	APC Probe	see APC		Entire gastro-intestinal tract	Injection needle: while injection if necessary with lower power/effect setting	
				 GastroCOAG	GastroCOAG	10–30 W			
			Incision	Needle instrument	 medium	GastroKNIFE			Effect 2–6
					 slow				
			Haemostasis	Hot Biopsy forceps	 GastroCOAG	GastroCOAG			10–30 W
					 GastroCOAG	GastroCOAG			10–30 W
					APC Probe	see APC			
APC	Standard		APC Probe	 Argon flexible	Argon flexible	30–60 W	Stomach, oesophagus	Gas Flow: 0,4 l/min	
					Arg. flexible pulse	Effect 1–3, 30–80 W			
				 Argon flexible	Argon flexible	5–20 W	Small intestine, right colon		
					 Pulsed 4.4kV	Arg. flexible pulse			Effect 1–3, 5–20 W
				 Argon flexible	Argon flexible	5–30 W	Colon transversum, left colon		
					Arg. flexible pulse	Effect 1–3, 5–30 W			

PROCEDURE	INDICATION	TECHNOLOGY	INSTRUMENT	MODE	SETTING	APPLICATION	NOTES	
APC	Haemostasis		APC Probe		Argon flexible	5–30 W		Gas Flow: 0,4 l/min
	Marker				Argon flexible	5–20 W		
	Devitalization				Argon flexible	30–80 W	Barrett's oesophagus / carcinoma	
					Arg. flexible pulse	Effect 1–3, 30–80 W	Zenker's diverticulum, Barrett's carcinoma (palliative)	
	Tumor treatment	Small tumor < 15 mm			Argon flexible	30–80 W		
		Large tumor > 15 mm			Argon flexible	30–80 W		
	Stenting	Ingrowth, overgrowth			Arg. flexible pulse	Effect 1–3, 30–80 W		
		Trimming			Argon flexible	30–60 W		
	Stenosis	Recanalisation, Debulking			Argon flexible	30–50 W	Barrett's cancer (palliative therapy)	
					Arg. flexible pulse	Effect 1–3, 30–50 W		
	Vascular malformation				Argon flexible	10–40 W	GAVE syndrome (watermelon stomach), angiodysplasia	
					Arg. flexible pulse	Effect 1–3, 10–40 W		

*BOWA-electronic GmbH has used utmost care during creation. Nevertheless, errors can not be completely excluded.

From the recommended settings and the information and data contained therein no claims against BOWA can be derived. If any legal liability arise, so it is limited to intent and gross negligence.

All information on recommended settings, application sites and the use of instruments are based on clinical experience. Individual centers and doctors favor regardless of the stated recommendations other settings.

The figures are only approximate and must be verified by the surgeon for their applicability.

Depending on the individual circumstances it may be necessary to deviate from the details given here.

Due to ongoing research and clinical experience, the medicine is constantly evolving. Those are reasons why it can be useful to deviate from the information contained herein.

4

DIAGNOSES AND RECOMMENDED PROCEDURES

Specific procedures are typically used to treat specific diagnoses. The following table lists examples of procedures and their relevant diagnoses. Please note that it may be necessary to deviate from this information, and that this will depend on the clinical situation and the specifications provided in the relevant specialty's professional guidelines. The relevant specialty's professional guidelines must be adhered to at all times.

PROCEDURE (AS PER OPS 2015
(GERMAN PROCEDURE CLASSIFICATION SYSTEM))

DIAGNOSIS (AS PER ICD 10-GM
(GERMAN MODIFICATION))

Local excision and destruction of diseased oesophageal tissue (5-422)	Zenker's diverticulum (K22.5)
(Endoscopic) sclerotherapy for oesophageal varices (5-429.1) Ligation of oesophageal varices (5-429.2) (Endoscopic) ligation (band ligation) oesophageal varices (5-429.a)	Oesophageal varices (I85)
Diagnostic upper gastrointestinal endoscopy (1-630) 1 to 5 biopsies of the upper alimentary canal (1-440.a) Multiple biopsies in upper gastrointestinal tract (1-440.9)	For diagnosis: Barrett's oesophagus (K22.7)
Endoscopic mucosal resection (5-422.23) Endoscopic mucosal dissection [ESD] (5-422.24)	Barrett's cancer (C15.2) Benign oesophageal neoplasms (D13.0)
Partial oesophageal resection and restoration of gastrointestinal continuity (5-424)	Barrett's cancer (applicable to tumours from category T1b, K22.7)
Destruction of diseased oesophageal tissue (endoscopy-based, 5-422.5)	Cervical inlet patch (Q39.4)
Endoscopic mucosal resection (5-422.23)	Malignant gastric neoplasms (C16, e. g. early gastric cancer)
Ligation or overstitching of gastric ulcer (5-449.5)	Bleeding ulcer Forrest Ib-III (K25.0 (acute) or K25.4 (chronic))
Tissue-closure using endoclips or injection (5-449.d and 5-449.e)	Gastric leak (other surgical complications not classified elsewhere T81.8)
Closure of gastrocutaneous fistula (5-448.1)	Persistent gastrocutaneous fistula (GCF) (K31.6)
Fundoplication (5-448.4)	Severe cases of reflux (gastro-oesophageal reflux disease K21)
Destruction of diseased gastric tissue (5-433.5)	GAVE syndrome (angiodysplasia of the stomach and small intestine with or without bleeding K31.81 or K31.82)
Diagnostic retrograde cholangiopancreatography (ERCP, 1-642)	For diagnosis: Jaundice, bile duct obstruction, pancreatitis, pancreatic cancer
Division of pancreatic sphincter by incision (Papillotomy, 5-513.1)	Gall stones (K80)
Snare polypectomy of 1-2 polyps (5-451.71) Snare polypectomy of more than 2 polyps (5-451.72) Endoscopic mucosal dissection [ESD] (5-451.74)	Polyps of small intestine (Benign neoplasms of sections of the small intestine not classified elsewhere D13.3)
Snare polypectomy of 1-2 polyps (5-452.21) Snare polypectomy of more than 2 polyps (5-452.22) Endoscopic mucosal dissection [ESD] (5-452.24)	Colon polyps (K63.5)
Oesophageal foreign body removal using flexible device (8-100.6)	Oesophageal foreign body (T18.1)

5

FAQ – BOWA ARC IN GASTROENTEROLOGY PRACTICE

What are the settings required when using snare devices?

When using snare-based devices/polypectomy snares with a BOWA generator, the generator should be set to the GastroLoop mode. In this mode, the operator can choose between 3 cutting speeds, depending on the patient's exact diagnosis and specifics of the procedure.

What are the settings required when using needle devices/papillotomes?

When using needle devices/papillotomes, the BOWA generator should be set to the GastroKnife mode. In this mode, the operator can choose between 3 cutting speeds, depending on the patient's exact diagnosis and specifics of the procedure.

What needs to be done when using hot biopsy forceps?

Always select the GastroCoag setting when using endoscopic grasping tools with HF input, irrespective of the exact diagnosis and target areas involved. The operator can choose between different coagulation techniques, depending on the patient's exact diagnosis and specifics of the procedure.

Would you recommend submucosal injection to lift the lesion?

BOWA recommends following the procedures outlined in the relevant endoscopy guidelines. Depending on the type and location of the lesion, submucosal injection can reduce the risk of perforation.

Is it necessary to use pre-coagulation prior to ablation of a lesion?

Under normal circumstances, pre-coagulation is not necessary because GastroCut has a coagulation feature. It may, however, be useful in specific situations (e.g. pedunculated polyp)

What exactly is BOWA GastroCut?

GastroCut is a special mode for endoscopy procedures, It is characterised by intermittent, and clearly defined cutting and coagulation phases.

How does GastroCut control tissue effects?

Tissue effects can be controlled via different effect settings. The higher the effect setting, the higher the coagulation effect.

Why are there no power settings with GastroCut?

Modern HF devices use automated power control, which means power is adjusted automatically depending on tissue characteristics and the desired tissue effects

How is GastroCut activated?

GastroCut is a type of cutting mode, and is therefore activated via the yellow foot pedal.

What are the advantages of APC coagulation?

Argon plasma coagulation (APC) is a non-contact technique that allows for easier handling and offers maximum protection against the risk of perforation.

How does the EASY system work?

The EASY system controls dual electrode return pads and detects the partial detachment of electrode pads. In the event of a malfunction, all monopolar input currents are deactivated, thereby minimising the risk of tissue burn at the electrode site.

A dynamic reference resistance value is selected when using the dispersal electrode. If the resistance value at the dispersal electrode is detected as 50% higher

than the reference value, the EASY system will deactivate all monopolar input currents. At the same time, an alarm will sound and an error message will be displayed.

What is the purpose of the BOWA ARC CONTROL?

The arc regulator is capable of adjusting the power output to the absolute minimum required to achieve reproducible tissue effects. This adjustment takes only a fraction of a second, and ensures that the current passing through the patient's body is no higher than absolutely necessary.

Why is the initial cutting support input needed?

The high-energy output cutting support phase allows the current arc to start up immediately, thus ensuring the device is easy to operate and progress is smooth. Delivery of the high energy output is limited to the brief initial cutting support phase, and the current is adjusted down within a fraction of a second. The powerful technology required for this feature is available with the ARC 400 and the ARC 350.

What are BOWA COMFORT leads used for?

RFID chips contained within the plugs allow devices to be identified automatically. This results in automatic pre-selection of all relevant parameters as soon as the appropriate power output for the procedure has been activated.

Can BOWA leads be used with other devices?

The leads were developed especially for use with BOWA ARC generators with COMFORT function, and are therefore not compatible with other devices.

Can the BOWA ARC generator be used for other clinical applications?

The BOWA ARC 400 is an electro-surgical device that is suitable for interdisciplinary use, and for all electro-surgical applications.

Can it be used with non-BOWA accessories?

Use of the appropriate connectors ensures all standard accessories can be used without the need for adapters.

Can the BOWA ARC 400 be used to seal blood vessels?

BOWA offers a LIGATION feature for the ARC 400, as well as numerous re-usable instruments for laparoscopy and open surgery procedures.

How many times can BOWA leads be used?

All BOWA leads with instrument recognition are guaranteed for 100 autoclave cycles.

Each use is logged by the instrument, and the information available for retrieval. The user is liable for any use beyond the lifetime specified.

How can one tell if an instrument or device is re-usable or for single-use only?

All BOWA products intended for single-use only are clearly marked with the 'single use' symbol.



It is imperative that the relevant instrument's instructions for use be followed.

6

REFERENCES

1. Hug B, Haag R. Hochfrequenzchirurgie. In: Kramme R, editor. *Medizintechnik*: Springer Berlin Heidelberg; 2011. p. 565-87.
2. Pointer DT, Jr., Slakey LM, Slakey DP. Safety and effectiveness of vessel sealing for dissection during pancreaticoduodenectomy. *The American surgeon*. 2013 Mar;79(3):290-5. PubMed PMID: 23461956.
3. Hefni MA, Bhaumik J, El-Toukhy T, Kho P, Wong I, Abdel-Razik T, et al. Safety and efficacy of using the LigaSure vessel sealing system for securing the pedicles in vaginal hysterectomy: randomised controlled trial. *BJOG : an international journal of obstetrics and gynaecology*. 2005 Mar;112(3):329-33. PubMed PMID: 15713149.
4. Berdah SV, Hoff C, Poornorooy PH, Razek P, Van Nieuwenhove Y. Postoperative efficacy and safety of vessel sealing: an experimental study on carotid arteries of the pig. *Surgical endoscopy*. 2012 Aug;26(8):2388-93. PubMed PMID: 22350233.
5. Gizzo S, Burul G, Di Gangi S, Lamparelli L, Saccardi C, Nardelli GB, et al. LigaSure vessel sealing system in vaginal hysterectomy: safety, efficacy and limitations. *Archives of gynecology and obstetrics*. 2013 Nov;288(5):1067-74. PubMed PMID: 23625333.
6. Overhaus M, Schaefer N, Walgenbach K, Hirner A, Szyrach MN, Tolba RH. Efficiency and safety of bipolar vessel and tissue sealing in visceral surgery. *Minimally invasive therapy & allied technologies : MITAT : official journal of the Society for Minimally Invasive Therapy*. 2012 Nov;21(6):396-401. PubMed PMID: 22292919.
7. Meier PN. Peptische Läsionen im Magen und Duodenum. *Empfehlungen der Deutschen Gesellschaft für Verdauungs- und Stoffwechselkrankheiten (DGVS) für die Durchführung endoskopischer Untersuchungen*. 3 ed: Demeter Verlag; 2002. p. 83-8.
8. Karaman A, Baskol M, Gursoy S, Torun E, Yurci A, Ozel BD, et al. Epinephrine plus argon plasma or heater probe coagulation in ulcer bleeding. *World journal of gastroenterology : WJG*. 2011 Sep 28;17(36):4109-12. PubMed PMID: 22039325. Pubmed Central PMCID: 3203362. Epub 2011/11/01. eng.
9. Greten H. *Innere Medizin* 2005.
10. Schepke MuS, T. Einsatz der Endoskopie bei Patienten mit Ösophagusvarizen. *Empfehlungen der Deutschen Gesellschaft für Verdauungs- und Stoffwechselkrankheiten (DGVS) für die Durchführung endoskopischer Untersuchungen*. 3 ed: Demeter Verlag; 2002. p. 76-83.
11. Yoshida H, Mamada Y, Taniai N, Yoshioka M, Hirakata A, Kawano Y, et al. Treatment modalities for bleeding esophagogastric varices. *Journal of Nihon Medical School = Nihon Ika Daigaku zasshi*. 2012;79(1):19-30. PubMed PMID: 22398787. Epub 2012/03/09. eng.
12. Hsu YC, Chung CS, Wang HP. Application of endoscopy in improving survival of cirrhotic patients with acute variceal hemorrhage. *International journal of hepatology*. 2011;2011:893973. PubMed PMID: 21994875. Pubmed Central PMCID: 3170849. Epub 2011/10/14. eng.
13. Voros D, Polydorou A, Polymeneas G, Vassiliou I, Melemeni A, Chondrogiannis K, et al. Long-term results with the modified Sugiura procedure for the management of variceal bleeding: standing the test of time in the treatment of bleeding esophageal varices. *World journal of surgery*. 2012 Mar;36(3):659-66. PubMed PMID: 22270986. Epub 2012/01/25. eng.
14. Biecker E, Heller J, Schmitz V, Lammert F, Sauerbruch T. Diagnosis and management of upper gastrointestinal bleeding. *Deutsches Arzteblatt international*. 2008 Feb;105(5):85-94. PubMed PMID: 19633792. Pubmed Central PMCID: PMC2701242. Epub 2008/02/01. eng.


15. Chiu YC, Lu LS, Wu KL, Tam W, Hu ML, Tai WC, et al. Comparison of argon plasma coagulation in management of upper gastrointestinal angiodysplasia and gastric antral vascular ectasia hemorrhage. *BMC gastroenterology*. 2012 Jun 9;12(1):67. PubMed PMID: 22681987. Pubmed Central PMCID: 3439282. Epub 2012/06/12. Eng.
16. Naga M, Esmat S, Naguib M, Sedrak H. Long-term effect of argon plasma coagulation (APC) in the treatment of gastric antral vascular ectasia (GAVE). *Arab journal of gastroenterology : the official publication of the Pan-Arab Association of Gastroenterology*. 2011 Mar;12(1):40-3. PubMed PMID: 21429455. Epub 2011/03/25. eng.
17. May A, Friesing-Sosnik T, Manner H, Pohl J, Ell C. Long-term outcome after argon plasma coagulation of small-bowel lesions using double-balloon enteroscopy in patients with mid-gastrointestinal bleeding. *Endoscopy*. 2011 Sep;43(9):759-65. PubMed PMID: 21544778. Epub 2011/05/06. eng.
18. Eickhoff A, Enderle MD, Hartmann D, Eickhoff JC, Riemann JF, Jakobs R. Effectiveness and Safety of PRECISE APC for the treatment of bleeding gastrointestinal angiodysplasia-- a retrospective evaluation. *Zeitschrift fur Gastroenterologie*. 2011 Feb;49(2):195-200. PubMed PMID: 21298605. Epub 2011/02/08. eng.
19. Gossner L, Ell C. Laser- und Elektrokoagulationsverfahren im Gastrointestinaltrakt. Empfehlungen der Deutschen Gesellschaft für Verdauungs- und Stoffwechselkrankheiten (DGVS) für die Durchführung endoskopischer Untersuchungen. 3 ed: Demeter Verlag; 2002. p. 239-51.
20. Silva RA, Correia AJ, Dias LM, Viana HL, Viana RL. Argon plasma coagulation therapy for hemorrhagic radiation proctosigmoiditis. *Gastrointestinal endoscopy*. 1999 Aug;50(2):221-4. PubMed PMID: 10425416. Epub 1999/07/30. eng.
21. Takemoto S, Shibamoto Y, Ayakawa S, Nagai A, Hayashi A, Ogino H, et al. Treatment and prognosis of patients with late rectal bleeding after intensity-modulated radiation therapy for prostate cancer. *Radiation oncology*. 2012;7:87. PubMed PMID: 22691293. Pubmed Central PMCID: 3403958. Epub 2012/06/14. eng.
22. Lenz L, Tafarel J, Correia L, Bonilha D, Santos M, Rodrigues R, et al. Comparative study of bipolar electrocoagulation versus argon plasma coagulation for rectal bleeding due to chronic radiation coloproctopathy. *Endoscopy*. 2011 Aug;43(8):697-701. PubMed PMID: 21611944. Epub 2011/05/26. eng.
23. Alvaro-Villegas JC, Sobrino-Cossio S, Tenorio-Tellez LC, de la Mora-Levy JG, Hernandez-Guerrero A, Alonso-Larraga JO, et al. Argon plasma coagulation and hyperbaric oxygen therapy in chronic radiation proctopathy, effectiveness and impact on tissue toxicity. *Revista espanola de enfermedades digestivas : organo oficial de la Sociedad Espanola de Patologia Digestiva*. 2011 Nov;103(11):576-81. PubMed PMID: 22149559. Epub 2011/12/14. eng spa.
24. Lenz L, Tafarel J, Correia L, Bonilha D, Monaghan M, Santos M, et al. The incidence of bacteraemia after argon plasma coagulation in patients with chronic radiation proctocolitis. *Colorectal disease : the official journal of the Association of Coloproctology of Great Britain and Ireland*. 2011 Jul;13(7):823-5. PubMed PMID: 20402735. Epub 2010/04/21. eng.
25. Sato Y, Takayama T, Sagawa T, Hirakawa M, Ohnuma H, Miyanishi K, et al. Argon plasma coagulation treatment of hemorrhagic radiation proctopathy: the optimal settings for application and longterm outcome. *Gastrointestinal endoscopy*. 2011 Mar;73(3):543-9. PubMed PMID: 21257166. Epub 2011/01/25. eng.
26. Rustagi T, Mashimo H. Endoscopic management of chronic radiation proctitis. *World journal of gastroenterology : WJG*. 2011 Nov 7;17(41):4554-62. PubMed PMID: 22147960. Pubmed Central PMCID: 3225092. Epub 2011/12/08. eng.
27. Shukuwa K, Kume K, Yamasaki M, Yoshikawa I, Otsuki M. Argon plasma coagulation therapy for a hemorrhagic radiation-induced gastritis in patient with pancreatic cancer. *Internal medicine*. 2007;46(13):975-7. PubMed PMID: 17603236. Epub 2007/07/03. eng.
28. Williamson JM, Almond LM, Shepherd NA, Barr H. Current management of Barrett's oesophagus. *British journal of hospital medicine*. 2012 May;73(5):271-7. PubMed PMID: 22585326. Epub 2012/05/16. eng.
29. Sharma P, Dent J, Armstrong D, Bergman JJ, Gossner L, Hoshihara Y, et al. The development and validation of an endoscopic grading system for Barrett's esophagus: the Prague C & M criteria. *Gastroenterology*. 2006 Nov;131(5):1392-9. PubMed PMID: 17101315. Epub 2006/11/15. eng.
30. Koop H, Schepp W, Muller-Lissner S, Madisch A, Micklefield G, Messmann H, et al. Consensus conference of the DGVS on gastroesophageal reflux. *Zeitschrift fur Gastroenterologie*. 2005 Feb;43(2):163-4. PubMed PMID: 15700206. Epub 2005/02/09. Gastroesophageale Refluxkrankheit -- Ergebnisse einer evidenzbasierten Konsensuskonferenz der Deutschen Gesellschaft für Verdauungs- und Stoffwechselkrankheiten. ger.
31. Messmann H, Ell C, Fein M, Kiesslich R, Ortner M, Porschen R, et al. Topic Complex VI: Barrett esophagus. *Zeitschrift fur Gastroenterologie*. 2005 Feb;43(2):184-90. PubMed PMID: 15700212. Epub 2005/02/09. Themenkomplex VI: Barrett-Osophagus. ger.
32. Nijhawan PK, Wang KK. Endoscopic mucosal resection for lesions with endoscopic features suggestive of malignancy and high-grade dysplasia within Barrett's esophagus. *Gastrointestinal endoscopy*. 2000 Sep;52(3):328-32. PubMed PMID: 10968845. Epub 2000/09/01. eng.
33. Behrens A, Pech O, Graupe F, May A, Lorenz D, Ell C. Barrett's adenocarcinoma of the esophagus: better outcomes through new methods of diagnosis and treatment. *Deutsches Arzteblatt international*. 2011 May;108(18):313-9. PubMed PMID: 21629515. Pubmed Central PMCID: 3103982. Epub 2011/06/02. eng.
34. Heuberger D, Manner H, Ell C, Pech O. How is Early Barrett's Cancer Currently Diagnosed and Treated in Western Europe? Results of a Survey at 52 University Hospitals in Eight Western European Countries. *Zeitschrift fur Gastroenterologie*. 2012 Jul;50(7):670-6. PubMed PMID: 22760678. Epub 2012/07/05. Wie werden Barrett-Fruhkarcinome in Westeuropa im klinischen Alltag diagnostiziert und therapiert? Ergebnisse einer Umfrage an 52 Unikliniken in 8 westeuropaischen Landern. Eng.

35. Fovos A, Jarral O, Panagiotopoulos N, Podas T, Mikhail S, Zacharakis E. Does endoscopic treatment for early oesophageal cancers give equivalent oncological outcomes as compared with oesophagectomy? Best evidence topic (BET). *International journal of surgery*. 2012 Jul 5;10(9):415-20. PubMed PMID: 22771501. Epub 2012/07/10. Eng.
36. Ono S, Fujishiro M, Koike K. Endoscopic submucosal dissection for superficial esophageal neoplasms. *World journal of gastrointestinal endoscopy*. 2012 May 16;4(5):162-6. PubMed PMID: 22624067. Pubmed Central PMCID: 3355238. Epub 2012/05/25. eng.
37. Herold G. *Innere Medizin* 2010.
38. Kolfenbach S, Malfertheiner P. Early gastric cancer--diagnosis and therapy. *Praxis*. 2006 Jun 21;95(25- 26):1037-41. PubMed PMID: 16836064. Epub 2006/07/14. Magenfrühkarzinom--Diagnostik und Therapie. ger.
39. Ell C, Gossner L, May A. Magenkarzinom und Magenpolypen. Empfehlungen der Deutschen Gesellschaft für Verdauungs- und Stoffwechselkrankheiten (DGVS) für die Durchführung endoskopischer Untersuchungen. 3 ed: Demeter Verlag; 2002. p. 88-95.
40. Ono H, Kondo H, Gotoda T, Shirao K, Yamaguchi H, Saito D, et al. Endoscopic mucosal resection for treatment of early gastric cancer. *Gut*. 2001 Feb;48(2):225-9. PubMed PMID: 11156645. Pubmed Central PMCID: 1728193. Epub 2001/01/13. eng.
41. Tomita T, Arai E, Kohno T, Kondo T, Kim Y, Oshima T, et al. Outcomes of treatment of argon plasma coagulation therapy in elderly or high-risk patients with early gastric cancer: a comparison of outcomes among experienced and nonexperienced endoscopists. *Journal of clinical gastroenterology*. 2011 Jul;45(6):e54-9. PubMed PMID: 20838235. Epub 2010/09/15. eng.
42. Schlemper RJ, Hirata I, Dixon MF. The macroscopic classification of early neoplasia of the digestive tract. *Endoscopy*. 2002 Feb;34(2):163-8. PubMed PMID: 11822013. Epub 2002/02/01. eng.
43. Gotoda T, Yanagisawa A, Sasako M, Ono H, Nakanishi Y, Shimoda T, et al. Incidence of lymph node metastasis from early gastric cancer: estimation with a large number of cases at two large centers. *Gastric cancer : official journal of the International Gastric Cancer Association and the Japanese Gastric Cancer Association*. 2000 Dec;3(4):219-25. PubMed PMID: 11984739. Epub 2002/05/02. Eng.
44. Schmiegel W, Pox C, Reinacher-Schick A, Adler G, Arnold D, Fleig W, et al. S3 guidelines for colorectal carcinoma: results of an evidence-based consensus conference on February 6/7, 2004 and June 8/9, 2007 (for the topics IV, VI and VII). *Zeitschrift für Gastroenterologie*. 2010 Jan;48(1):65-136. PubMed PMID: 20072998. Epub 2010/01/15. eng.
45. Lee SH, Shin SJ, Park DI, Kim SE, Jeon HJ, Kim SH, et al. Korean guideline for colonoscopic polypectomy. *Clinical endoscopy*. 2012 Mar;45(1):11-24. PubMed PMID: 22741130. Pubmed Central PMCID: 3363129. Epub 2012/06/29. eng.
46. Deyhle P. Results of endoscopic polypectomy in the gastrointestinal tract. *Endoscopy*. 1980 (Suppl):35-46. PubMed PMID: 7408789. Epub 1980/01/01. eng.
47. Fruhmorgen PK, L. Guidelines of the German Society of Digestive and Metabolic Diseases. Guidelines for endoscopic colorectal polypectomy with the sling. *German Society of Digestive and Metabolic Diseases. Zeitschrift für Gastroenterologie*. 1998 Feb;36(2):117- 9. PubMed PMID: 9544494. Epub 1998/04/17. Leitlinien der Deutschen Gesellschaft für Verdauungs- und Stoffwechselkrankheiten (DGVS). Leitlinien zur endoskopischen Ektomie kolorektaler Polypen mit der Schlinge. ger.
48. Zauber AG, Winawer SJ, O'Brien MJ, Lansdorf-Vogelaar I, van Ballegoijen M, Hankey BF, et al. Colonoscopic polypectomy and long-term prevention of colorectal-cancer deaths. *The New England journal of medicine*. 2012 Feb 23;366(8):687-96. PubMed PMID: 22356322. Pubmed Central PMCID: 3322371. Epub 2012/02/24. eng.
49. Vormbrock K, Monkemüller K. Difficult colon polypectomy. *World journal of gastrointestinal endoscopy*. 2012 Jul 16;4(7):269-80. PubMed PMID: 22816006. Pubmed Central PMCID: 3399004. Epub 2012/07/21. eng.
50. Moss A, Bourke MJ, Williams SJ, Hourigan LF, Brown G, Tam W, et al. Endoscopic mucosal resection outcomes and prediction of submucosal cancer from advanced colonic mucosal neoplasia. *Gastroenterology*. 2011 Jun;140(7):1909-18. PubMed PMID: 21392504. Epub 2011/03/12. eng.
51. Toyokawa T, Inaba T, Omote S, Okamoto A, Miyasaka R, Watanabe K, et al. Risk factors for perforation and delayed bleeding associated with endoscopic submucosal dissection for early gastric neoplasms: analysis of 1123 lesions. *Journal of gastroenterology and hepatology*. 2012 May;27(5):907-12. PubMed PMID: 22142449. Epub 2011/12/07. eng.
52. Uraoka T, Saito Y, Yahagi N. What are the latest developments in colorectal endoscopic submucosal dissection? *World journal of gastrointestinal endoscopy*. 2012 Jul 16;4(7):296-300. PubMed PMID: 22816009. Pubmed Central PMCID: 3399007. Epub 2012/07/21. eng.
53. Deutsche Gesellschaft für Verdauungs- und Stoffwechselkrankheiten KfB. Endoskopische Vollwandresektion am Kolon. In: Schepp W, editor.: *Deutsches Institut für Medizinische Dokumentation und Information*; 2015.
54. Tsiamoulos ZP, Bourikas LA, Saunders BP. Endoscopic mucosal ablation: a new argon plasma coagulation/injection technique to assist complete resection of recurrent, fibrotic colon polyps (with video). *Gastrointestinal endoscopy*. 2012 Feb;75(2):400-4. PubMed PMID: 22154411. Epub 2011/12/14. eng.
55. Udd M, Kylanpää L, Halttunen J. Management of difficult bile duct cannulation in ERCP. *World journal of gastrointestinal endoscopy*. 2010 Mar 16;2(3):97-103. PubMed PMID: 21160709. Pubmed Central PMCID: 2999064. Epub 2010/12/17. eng.
56. Weber A, Roesch T, Pointner S, Born P, Neu B, Meining A, et al. Transpancreatic precut sphincterotomy for cannulation of inaccessible common bile duct: a safe and successful technique. *Pancreas*. 2008 Mar;36(2):187-91. PubMed PMID: 18376311. Epub 2008/04/01. eng.

57. Meier PN. Zenker's diverticulum: pro endoscopic treatment. *Der Chirurg; Zeitschrift für alle Gebiete der operativen Medizen.* 2011 Jun;82(6):479-80, 82-3. PubMed PMID: 21553134. Epub 2011/05/10. Zenker-Divertikel: Pro endoskopische Septumdurchtrennung. ger.
58. Ferreira LE, Simmons DT, Baron TH. Zenker's diverticula: pathophysiology, clinical presentation, and flexible endoscopic management. *Diseases of the esophagus : official journal of the International Society for Diseases of the Esophagus / ISDE.* 2008;21(1):1-8. PubMed PMID: 18197932. Epub 2008/01/17. eng.
59. Case DJ, Baron TH. Flexible endoscopic management of Zenker diverticulum: the Mayo Clinic experience. *Mayo Clinic proceedings Mayo Clinic.* 2010 Aug;85(8):719-22. PubMed PMID: 20675509. Pubmed Central PMCID: 2912732. Epub 2010/08/03. eng.
60. Al-Kadi AS, Maghrabi AA, Thomson D, Gillman LM, Dhalla S. Endoscopic treatment of Zenker diverticulum: results of a 7-year experience. *Journal of the American College of Surgeons.* 2010 Aug;211(2):239-43. PubMed PMID: 20670862. Epub 2010/07/31. eng.
61. Rabenstein T, May A, Michel J, Manner H, Pech O, Gossner L, et al. Argon plasma coagulation for flexible endoscopic Zenker's diverticulotomy. *Endoscopy.* 2007 Feb;39(2):141-5. PubMed PMID: 17327972. Epub 2007/03/01. eng.
62. Stavropoulos SN, Modayil R, Friedel D. Per oral endoscopic myotomy for the treatment of achalasia. *Curr Opin Gastroenterol.* 2015 Sep;31(5):430-40. PubMed PMID: 26200001.
63. Friedel D, Modayil R, Stavropoulos SN. Per-oral endoscopic myotomy: major advance in achalasia treatment and in endoscopic surgery. *World journal of gastroenterology : WJG.* 2014 Dec 21;20(47):17746-55. PubMed PMID: 25548473. Pubmed Central PMCID: PMC4273125.
64. Definition. Debulking. Available from: <http://www.enzyklo.de/Begriff/Debulking>.
65. Zenker M. Argon plasma coagulation. *GMS Krankenhaushygiene interdisziplinär.* 2008;3(1):Doc15. PubMed PMID: 20204117. Pubmed Central PMCID: 2831517. Epub 2008/01/01. eng.
66. Raithe M, Hänslér J, Stegmaier A, Boxberger F, Maiss J, Wiegand M, et al. Prospektive, randomisierte Evaluation der Niedrig-Energie- Argonplasmakoagulation bei der endoskopischen Blutstillung am Gastrointestinaltrakt (GIT). *Endo heute.* 2007 // 16.03.2007;20(01):P4. De.
67. Raithe M, Hänslér J, Nägel A, Hahn EG. Anwendbarkeit, Effektivität und Sicherheit der BOWA Generatoren und Argoneinheit in der gastroenterologischen Endoskopie. *Endo heute.* 2006 // 20.03.2006;19(01):P29. De.
68. Rupinski M, Zagorowicz E, Regula J, Fijuth J, Kraszewska E, Polkowski M, et al. Randomized comparison of three palliative regimens including brachytherapy, photodynamic therapy, and APC in patients with malignant dysphagia (CONSORT 1a) (Revised II). *The American journal of gastroenterology.* 2011 Sep;106(9):1612-20. PubMed PMID: 21670770. Epub 2011/06/15. eng.
69. Kofoed SC, Lundsgaard M, Ellemann AC, Svendsen LB. Low morbidity after palliation of obstructing gastro-oesophageal adenocarcinoma to restore swallowing function. *Danish medical journal.* 2012 Jun;59(6):A4434. PubMed PMID: 22677236. Epub 2012/06/09. eng.
70. Ramadori G, Lindhorst A, Armbrust T. Colorectal tumors with complete obstruction--endoscopic recovery of passage replacing emergency surgery? A report of two cases. *BMC gastroenterology.* 2007;7:14. PubMed PMID: 17391506. Pubmed Central PMCID: 1847445. Epub 2007/03/30. eng.
71. Boxberger F, Maiss J, Amann K, Janka R, Wein A, Maennlein G, et al. Severe high grade stenosing hyperkeratosis of the esophagus after ingestion of alkali: successful treatment by argon plasma coagulation. *Endoscopy.* 2008 Sep;40 Suppl 2:E260-1. PubMed PMID: 19090458. Epub 2008/12/19. eng.
72. Behrens C, Yen PP. Esophageal inlet patch. *Radiology research and practice.* 2011;2011:460890. PubMed PMID: 22091379. Pubmed Central PMCID: 3197178. Epub 2011/11/18. eng.
73. Chen YR, Wu MM, Nan Q, Duan LP, Miao YL, Li XY. Heterotopic gastric mucosa in the upper and middle esophagus: 126 cases of gastroscopy and clinical characteristics. *Hepatogastroenterology.* 2012 Jun;59(116):1123-5. PubMed PMID: 22580663. Epub 2012/05/15. eng.
74. Bajbouj M, Becker V, Eckel F, Miehke S, Pech O, Prinz C, et al. Argon plasma coagulation of cervical heterotopic gastric mucosa as an alternative treatment for globus sensations. *Gastroenterology.* 2009 Aug;137(2):440-4. PubMed PMID: 19410576. Epub 2009/05/05. eng.
75. Sauve G, Croue A, Denez B, Boyer J. High-grade dysplasia in heterotopic gastric mucosa in the upper esophagus after radiotherapy: successful eradication 2 years after endoscopic treatment by argon plasma coagulation. *Endoscopy.* 2001 Aug;33(8):732. PubMed PMID: 11490394. Epub 2001/08/08. eng.
76. Wang L, Fan CQ, Ren W, Zhang X, Li YH, Zhao XY. Endoscopic dissection of large endogenous myogenic tumors in the esophagus and stomach is safe and feasible: a report of 42 cases. *Scandinavian journal of gastroenterology.* 2011 May;46(5):627-33. PubMed PMID: 21366494. Epub 2011/03/04. eng.
77. Piper W. *Innere Medizin.* Springer-Verlag, editor2007.
78. Fernandez-Esparrach G, Lautz DB, Thompson CC. Peroral endoscopic anastomotic reduction improves intractable dumping syndrome in Roux-en-Y gastric bypass patients. *Surgery for obesity and related diseases : official journal of the American Society for Bariatric Surgery.* 2010 Jan-Feb;6(1):36-40. PubMed PMID: 19560979. Epub 2009/06/30. eng.
79. Gossner L, Ell C. Refluxösophagitis und prä-maligne Läsionen des Ösophagus. *Empfehlungen der Deutschen Gesellschaft für Verdauungs- und Stoffwechselkrankheiten (DGVS) für die Durchführung endoskopischer Untersuchungen.* 3 ed: Demeter Verlag; 2002. p. 57-65.

We are extremely grateful for the help provided by Prof. Dr. med. Jörg Albert .

FOR YOUR NOTES



BOWA

A C A D E M Y

BOWA-electronic GmbH & Co. KG
Heinrich-Hertz-Straße 4-10
72810 Gomaringen | Germany

Telefon +49 (0) 7072-6002-0
Telefax +49 (0) 7072-6002-33
info@bowa.de | bowa.de

